

## Optical Coherence Tomography Angiography Findings in Radiation Retinopathy: A Case Report

Ammari W<sup>1\*</sup>, Zaghoudi A<sup>1</sup>, Berriche O<sup>2</sup>, Mbarek S<sup>1</sup>, Abid F<sup>1</sup>, Khairallah M<sup>1</sup>, Mahmoud A<sup>1</sup> and Messaoud R<sup>1</sup>

<sup>1</sup>Department of Ophthalmology, University Hospital Taher Sfar Mahdia, Tunisia

<sup>2</sup>Department of Medicine Internal, University Hospital Taher Sfar Mahdia, Tunisia

### \*Corresponding author:

Wafa Ammari,  
Department of Ophthalmology, University  
Hospital Taher Sfar Mahdia, Tunisia,  
E-mail: wafa.ammari@yahoo.fr

Received: 11 Jun 2022

Accepted: 21 Jun 2022

Published: 27 Jun 2022

J Short Name: COO

### Copyright:

©2022 Ammari W. This is an open access article distributed under the terms of the Creative Commons Attribution License, which permits unrestricted use, distribution, and build upon your work non-commercially.

### Keywords:

Superficial retinal capillary plexus; Deep retinal capillary plexus; Ischemic cascade; Radiation retinopathy; OCT angiography

### Citation:

Ammari W, Optical Coherence Tomography Angiography Findings in Radiation Retinopathy: A Case Report. Clin Onco. 2022; 6(7): 1-8

### 1. Abstract

We report the observation of a 31-year-old patient followed for nasopharyngeal carcinoma since 2009, treated by locoregional radiotherapy, with a cumulative dose of 70 Grays. She presented with a progressive decline in bilateral visual acuity. Ophthalmologic examination reveals bilateral posterior subcapsular cataract, radiation retinopathy, and optic neuropathy. The optical coherence tomography OCT B-scan showed more pronounced macular edema in the right eye. The OCTA reveals enlargement of the central avascular zone and loss of the deep and superficial retinal vascular network. The patient received three consecutive monthly intravitreal injections of anti VEGF, without improvement in visual acuity.

The aim of this case report is to study, the contribution of optical coherence tomography angiography (OCTA) in the diagnosis of radiation maculopathy, and attribute these changes to ischemia at the level of the retinal vascular network.

### 2. Introduction

Locoregional radiotherapy is the most effective treatment against nasopharyngeal carcinoma [1]. However late-onset sight-threatening ocular complications may occur, these include cataract, optic neuropathy, radiation retinopathy, and ocular surface disease [2].

We report a case of radiation retinopathy in a 31-year-old female with nasopharyngeal carcinoma (NPC), treated by locoregional Radiation Therapy (RT).

The purpose of this case report is to analyze the findings and the usefulness of Optical Coherence Tomography Angiography

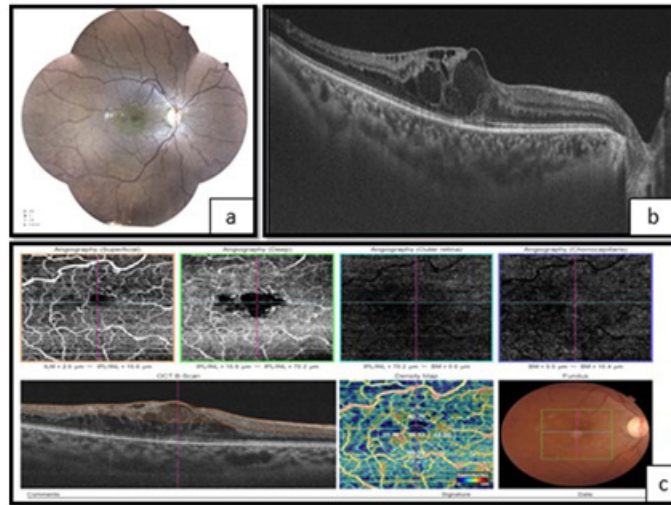
(OCTA) in this disease.

### 3. Case Report

A 31-year-old female with a history of nasopharyngeal carcinoma was diagnosed in 2009 and treated by locoregional radiotherapy. The overall administered dose was about 75 Gy. She was presented with adrenal insufficiency, hypothyroidism, and osteonecrosis as side effects of the treatment. She has complained of progressive painless loss of vision in both eyes. On examination, her best-corrected visual acuity was 20/40 in both eyes. The ocular motility was full, and no afferent pupillary defect was noted. A symmetrical subcapsular cataract was found. The rest of the anterior segment examination was unremarkable. No vitreous cells were noted. Fundoscopy showed microvascular changes mainly marked by vascular tortuosity and microaneurysms, optic disc pallor, and decreased foveal reflex. Fluorescein angiography was not performed because the patient was allergic to fluorescein. Optical Coherence Tomography in B-scan showed bilateral macular edema with a respectively central macular thickness of 532  $\mu\text{m}$  in the Right Eye (RE), and 406  $\mu\text{m}$  in the Left Eye (LE). OCT Angiography (OCT-A) disclosed enlargement of the central avascular zone, and hypoperfusion of both superficial and deep retinal capillary networks (Figures 1 and 2). The vessel density was reduced to 38,12 % in the inferior macular area of the RE, and to 39,34 % in the superior macular area of the LE. A systemic workup was performed to rule out other causes of ischemic retinopathy (diabetes mellitus, blood dyscrasias, and carotid insufficiency). Based on medical history, ocular findings, and negative systemic workup

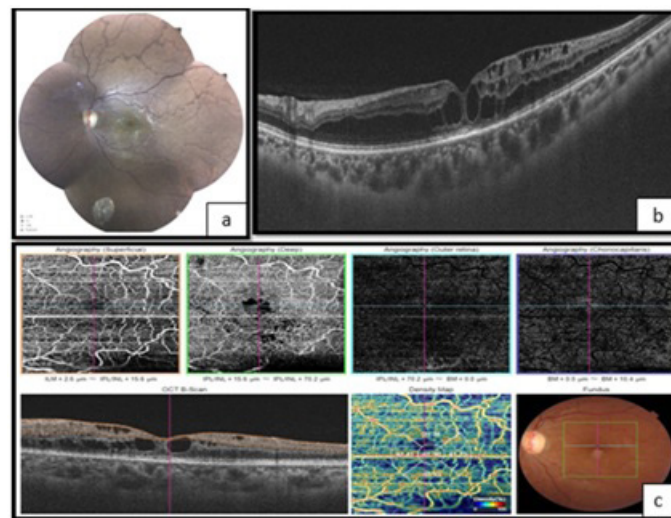
the diagnosis of radiation retinopathy was finally established. After informed consent, and a negative pregnancy test, the patient

underwent three monthly intravitreal bevacizumab injections (1.25 mg). The improvement of visual acuity was poor.



**Figure 1:** Right eye

- a. Fundoscopy showing vascular tortuosity and dilation of peripheral retinal vessels, the disappearance of foveolar reflection, and mild pallor of the optic disc
- b. The OCT shows macular edema
- c. OCT-A showing enlargement of the central avascular zone, and hypoperfusion of both superficial and deep retinal capillary network



**Figure 2:** Left eye

- a. Fundoscopy showing vascular tortuosity and dilation of peripheral retinal vessels, the disappearance of foveolar reflection, and mild pallor of the optic disc
- b. The OCT showing macular edema
- c. OCT-A showing enlargement of the central avascular zone, and hypoperfusion of both superficial and deep retinal capillary network

#### 4. Discussion

Radiation Retinopathy (RR) was first described in 1933 by Stallard [3], as a predictable complication of radiation exposure. It most commonly occurs between 6 months and 3 years after irradiation [4]. A higher total radiation dose is the most risk factor, the incidence of RR increases at doses greater than 45 Gy. Histopathological studies have illustrated a vasculopathy with the destruction of the endothelial cells followed by vascular occlusion and capillary dropout [3, 4]. The microvascular alterations are associated with a

reduction of retinal oxygenation and blood flow, so ischemia [2, 3, 4]. Contrast sensitivity decrease and visual field impairment were notified in patients treated with radiotherapy [1]. Our patient had bilateral decreased visual acuity gradually, but she also had cataract and optic neuropathy. The clinical appearance mimics many lesions of diabetic retinopathy such as microaneurysms, macular edema, cotton-wool spots, retinal neovascularization, vitreous hemorrhage, and tractional retinal detachment [4]. The main tests performed on patients were Fluorescein Fundus Angiography (FFA) and Optical Coherence Tomography (OCT). The first exam

hallmarks are capillary dilatation and microaneurysms, frequently in combination with ischemia or macular edema [5]. On Optical Coherence Tomography (OCT) images, there is a disappearance of the macular depression with macular edema, a significant thinning of the inner plexiform, inner nuclear, and outer plexiform layers [5]. However, FFA is an invasive diagnostic technique. Intravenous dyes injection used may cause severe anaphylaxis; particularly in immunocompromised patients. It's not performed for our patient. Besides, OCT cannot capture vessel network status. Recently, Optical Coherence Tomography Angiography (OCTA), is a safe and non-invasive examination, that combines traditional OCT and FFA. It can provide high-resolution images of each layer of the retina and quantify the retinal microvascular networks without the use of exogenous dyes. OCTA has been introduced for the detection of subtle microvascular changes in radiation retinopathy [6, 7]. Vascular abnormalities are manifested by an enlargement of the central avascular zone and a reduction of vessel density in the deep vascular plexus of the foveal area. Whereas it's less reduced in superficial layers. The susceptibility of the deep layer can be explained by the direct connection of the superficial capillary plexus to the retinal arterioles with greater perfusion and oxygen supply [3]. Either this change in structure can be explained by direct compression of the retinal vascular network, deep in the first place, by intra-retinal fluid cysts. Li et al. [1] found that OCTA detects early vascular alterations of the retina in patients with normal-ranged visual acuity. It provided a quantitative measurement of retinal capillary changes which may predict future development of radiation-induced retinal toxicity [5]. They suggest the implementation of OCTA for the early detection and consistent monitoring of RR. In this sense, a grading system was proposed based on clinical findings in OCTA, increased central macular thickness, evident cysts, and ophthalmoscopy findings [5]. The disadvantage is the presence of several artifacts, especially after treatment.

Furthermore, due to the clinical and pathophysiological similarities with diabetic retinopathy, the treatment of radiation retinopathy is inspired by it [8]. Initially, treatments were based on the use of retinal laser [8]. Sector photocoagulation improves clinical signs, but the visual outcome is poor [8]. Intravitreal injection of anti-VEGF or corticosteroids has been shown to improve visual acuity, reduce cystoid macular edema, and the risk of the development of radiation retinopathy [3, 8]. The visual acuity of our patient didn't change, probably because she presents several complications of local radiotherapy such as cataract and optic neuropathy, and ischemia affecting deep layers. Continuous treatment is necessary to maintain acuity improvement [7]. It requires good patient adherence [8]. The optimal regimen for anti-VEGF therapy is not yet identified [7]. There are recent preventive efforts to avoid signs that radiation damage has already occurred, particularly since there is still no curative treatment [9].

## 5. Conclusion

Radiation retinopathy manifests itself on optical coherence tomography angiography by an enlargement of the foveolar avascular zone and a rarefaction of the vascular network at the level of the deep and vascular networks, even in eyes without clinical evidence of radiation retinopathy.

## References

1. Zijing L, Zongyi Z, Jianhui X, Yuqing L. Radiation-Induced Optical Coherence Tomography Angiography Retinal Alterations in Patients with Nasopharyngeal Carcinoma. *Front Med (Lausanne)*. 2020; 7: 630880.
2. Akagunduz OO, Yilmaz SG, Tavlayan E, Baris ME, Afrashi F, Esas-solak M. Radiation-Induced Ocular Surface Disorders and Retinopathy: Ocular Structures and Radiation Dose-Volume Effect. *Cancer Res Treat*. 2021.
3. Rose K, Krema H, Durairaj P, Dangboon W, Chavez Y, Kulasekara SI, Hudson C. Retinal perfusion changes in radiation retinopathy. *Acta Ophthalmology*. 2018; 96(6):e727-e731.
4. Wang D, Au A, Duker JS, Sarraf D. PAMM and the ischemic cascade associated with radiation retinopathy. *Am J Ophthalmol Case Report*. 2020; 20:100918.
5. Skalet AH, Liu L, Binder C, Miller AK, Crilly R, Hung AY, Wilson DJ, Huang D, Jia Y. Longitudinal Detection of Radiation-Induced Peripapillary and Macular Retinal Capillary Ischemia Using OCT Angiography. *Ophthalmol Retina*. 2020; 4(3): 320-326.
6. Seibel I, Vollhardt D, Riechardt AI, Rehak M, Schmied S, Schiller P, Zeitz O, Hellmich M, Jousseaume AM. Influence of Ranibizumab versus laser photocoagulation on radiation retinopathy (RadiRet) -a prospective randomized controlled trial. *Graefes Arch Clin Exp Ophthalmol*. 2020; 258(4): 869-878.
7. Fallico M, Chronopoulos A, Schutz JS, Reibaldi M. Treatment of radiation maculopathy and radiation-induced macular oedema: A systemic review. *Surv Ophthalmology*. 2021; 66(3):441-60.
8. T Say EA, Ferenczy S, Magrath GN, Samara WA, L Khoo CT, L Shields C. Image Quality and Artifacts on Optical Coherence Tomography Angiography: Comparison of Pathologic and Paired Fellow Eyes in 65 Patients with Unilateral Choroidal Melanoma Treated with Plaque Radiotherapy. *Retina*. 2017; 37(9):1660-73.
9. Reichstein D. Current treatments and preventive strategies for radiation retinopathy. *Curr Opin Ophthalmol*. 2015; 26(3): 157-66.