

The Black Fungus is One of the Bad Consequences of COVID 19

Elbossaty WF*

Department of Biochemistry, Damietta University, Damietta, Egypt

*Corresponding author:

Walaa Fikry Elbossaty,
Department of Biochemistry, Damietta University,
Damietta, Egypt,
E-mail: walaafikry1985@gmail.com

Received: 27 May 2021

Accepted: 09 June 2021

Published: 15 June 2021

Copyright:

©2021 Elbossaty WF et al. This is an open access article distributed under the terms of the Creative Commons Attribution License, which permits unrestricted use, distribution, and build upon your work non-commercially.

Citation:

Elbossaty WF, The Black Fungus is One of the Bad Consequences of COVID 19. Clin Onco. 2021; 5(2): 1-4

Keywords:

Mucormycosis; Black fungus; COVID19; Pandemic

1. Abstract

Recently, since the emergence of the Covid 19 pandemic, the whole world has been waiting for what comes after Corona and when that pandemic will disappear and how to get rid of it. Therefore, all countries, whether Arab or foreign, sought to empty scientific research to produce a vaccine to treat this pandemic. These circumstances have inflicted material and human losses for all countries. In an attempt to combat Covid 19 after the vaccine was manufactured, however, the winds are coming in what ships do not desire, so there is a new outbreak, namely the black fungus. The black fungus is a pathological phenomenon that arises as a result of exposure to mucormycosis and is observed concurrent with recovery from the virus.

The infection has symptoms and risks that do not reduce the risk of infection with Covid 19. Therefore, countries at the present time seek only to develop ways that are compatible with the current situation with the use of eye antibiotics. In this review, information about the new pandemic and awareness of its risks will be summarized.

2. Background

Mucormycosis is a rare fungal infection that occurs as a result of infection with fungal mucus found in soil, compost, plants and fruits, in addition to the presence in the nasal mucus of healthy people. Infection with the black fungus is widespread throughout the world, although it is rare. In the period between 1992-1993, the number of infected people in the San Francisco Bay Area was estimated at approximately 1.7 cases per million people. India is one of the countries with the largest spread of the disease, and this

is due to the high number of people with diabetes, as these diseases are the most vulnerable groups [1, 2]. It may also be due to high humidity, which increases the spread of fungi with it [3].

Where nearly 3,200 cases were registered in five states, Maharashtra, Madhya Pradesh, Haryana, Telangana and Gujarat. Maharashtra state is considered one of the most prevalent countries, with nearly 2,800 people infected and 90 deaths [4].

As this fungus affects the sinuses, the brain and the lung, in addition to being a very dangerous factor that may reach the point of death if the death rate due to infection with the fungus reaches nearly 50%, especially in patients with diabetes and immunodeficiency diseases [5].

One of the hypotheses about the relationship between the black fungus and the infection with Covid 19 is the treatment protocol, as the protocol relies on administering steroid drugs such as cortisone, which despite its usefulness in treating lung infections associated with the Covid 19 virus, but one of its serious harm is that it reduces the work of the immune system and weakens it, which facilitates Mucormycosis infection process [6].

It was found that there is a relationship between diabetes, Covid 19, and mucous fungus, as diabetes weakens the immunity, which helps in the attack of Covid 19 virus. At the time, they were infected with the mucous fungus, especially in the recovery phase from the virus, and the eyes of eleven patients were removed to save their lives [7].

3. Types of Mucormycosis

Mucormycosis types are summarized in Figure 1 [8].




Figure 1: Types of mucormycosis

3.1. Rhinocerebral mucormycosis: It is intended to afflict the sinuses and the brain, and this type is more prevalent in uncontrolled diabetics, and those with kidneys.

3.2. Pulmonary mucormycosis: intended to injure the lung and this type is more common in patients with cancer, or those who have undergone organ or stem cell transplantation.

3.4. Gastrointestinal mucormycosis: It is more common in children, especially low-weight chicks, who are less than a month old, and have taken antibiotics that weaken the immune system.

3.5. Cutaneous mucormycosis: The infection occurs in people who do not suffer from any immune problems. However, the fungus enters through cracks in the skin as a result of scratches or

burns and begins to spread from one organ to another, and often the brain is the target organ, and it may be transmitted Injury to the heart and spleen.

4. Symptoms of Mucormycosis

The disease suffers from black fungus with stuffy and nosebleeds, eye inflammation, drooping eyelids, all of which eventually leads to vision loss. At that time, the eye must be removed to prevent the infection from reaching the brain. In addition, in some cases, the jaw is removed to prevent the infection from spreading, in addition to high temperature, swelling of the face, skin ulcers, blackening around the mouth, chest pain, difficulty breathing, double vision, and coughing up blood, Figure 2 [9].

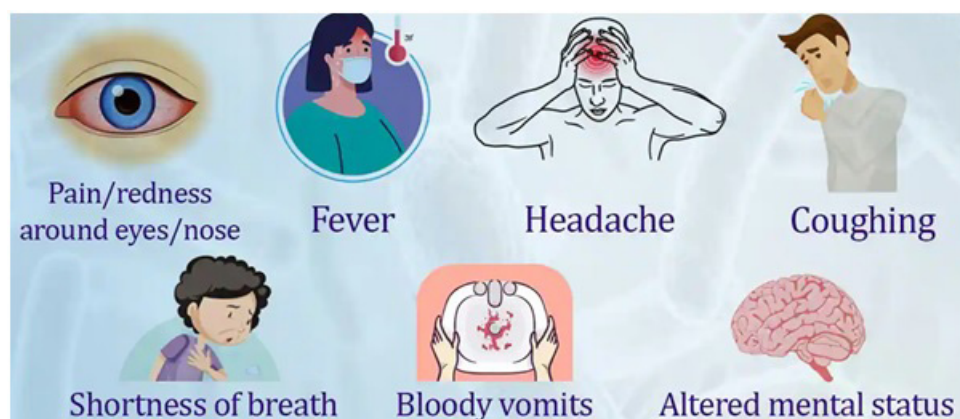


Figure 2: Black Fungus symptoms

4.1. Symptoms may vary depending on the affected organ

In the case of Rhinocerebral mucormycosis, swelling of the face on one side, pain in the head, congestion of the nose or sinuses, blackening of the tip of the nose [10].

In Pulmonary mucormycosis the symptoms are in the form of fever, headache, pain in the head, shortness of breath, and the ap-
clincisofoncology.com

pearance of blisters and ulcers, which are followed by redness of the wound, high temperature and swelling [11].

In gastrointestinal mucormycosis, symptoms appear as abdominal pain, nausea and vomiting, gastrointestinal bleeding [12].

In Cutaneous mucormycosis, the infection is in the form of blisters and ulcers that quickly swell and reddish and be accompanied by

high temperature, and their color may change, indicating that they are rotting due to lack of blood flow to them, which necessitates their removal so as not to harm the rest of the organs [13].

5. Pathogenesis of Mucormycosis

The disease begins as a skin infection in the air sinuses located behind the forehead, nose, cheekbones, and between the eyes and teeth. Then the infection spreads to the eyes, then the lung, and the spread may reach the brain. It is likely that the black fungus has moved through the blood circulation as it harms the organs due to the inability of blood to reach it, so it loses its function and dies and this is known as necrosis. This is when the organ becomes black and must be removed to prevent the infection from spreading to the rest of the organs. In some severe injuries, it travels through the blood circulation to the brain, causing blindness and creating gaps in the face. If it is not controlled, the death rate rises between 20-50%. The death rates depend on the type of fungi and the affected organ, so the sinus infection is mild compared to the severe injuries in the case of lung injury [14].

6. Diagnosis of Mucormycosis

It is done by making a cotton swab from the nose and examining it under a microscope. With some routine analysis such as blood, kidney function, CT scans, and if required, MRI is done to prove the injury [15].

7. Treatment of Mucormycosis

Anti-fungal injection is considered the most appropriate and effective method of treatment, but the problems facing the treatment plan are very costly, since the treatment period may be extended to 8 months. Among the most popular compounds used is Amphotericin B, and the treatment period ranges to 6 weeks until the patient reaches recovery. In some severe cases, the treatment plan requires the removal of the parts that have been damaged to prevent spread and maintain the patient's health so that his life does not end [16].

Isavuconazole has recently been used as a treatment with FDA approval. Some studies have proven the ability of hyperbaric oxygen to treat black fungus, since high-pressure oxygen has the ability to raise the efficiency of neutrophils to eliminate fungi [17].

8. The Link between COVID 19 and Black Fungus

There is a relationship between Covid 19 and the infection of patients with it with the black fungus, which can be summarized [18, 19]:

- As the fungi infect a person while he is in a state of immunodeficiency, and this case is closely related to COVID 19, whose symptoms are immunodeficiency and weakening of the immune system, in addition to the medicines that are taken during the period of infection, such as steroids, that are sufficient to suppress the immune system and thus facilitate penetration of the black fungus For cells.

- Also, most of the COVID 19 disease was confined to in-clinicsofoncology.com

tensive care under oxygen devices. In this case, the humidity is high and the fungi are easily infected.

References

1. Walaa F. Potential Effect of Micornas as Biomarkers and Therapeutic Targets in COVID-19. *J Gynecol Women's Health*. 2021; 20(5): 1-3.
2. Walaa F. Low Plasma Cholecalciferol as Independent Risk Factor for Covid19 Infection. *Biomed J Sci & Tech Res*. 2021; 33(3)-.
3. Rajendra S, Muddana K, Bakki S. Fungal Infections of Oral Cavity: Diagnosis, Management, and Association with COVID-19. *SN Compr. Clin. Med*. 2021.
4. Ghosh P, Ghosh R, Chakraborty B. COVID-19 in India: Statewise Analysis and Prediction. *JMIR Public Health Surveill*. 2020; 6(3): e20341.
5. Górska K, Błaszowska J, Dzikowiec M. Neuroinfections caused by fungi. *Infection*. 2018; 46(4): 443-59.
6. Mbaba AN, Ogolodom MP, Abam R, Akram M, Alazigha N, et al. Willingness of Health Care Workers to Respond to Covid-19 Pandemic in Port Harcourt, Nigeria. *Health Sci J*. 2021; 15(1): 802.
7. Kim JS, Lee JY, Yang JW, et al. Immunopathogenesis and treatment of cytokine storm in COVID-19. *Theranostics*. 2021; 11(1): 316-29.
8. Philipp K, Matteo B, Arunaloake C, Sharon C, et al. Defining and managing COVID-19-associated pulmonary aspergillosis: the 2020 ECMM/ISHAM consensus criteria for research and clinical guidance. *The Lancet Infectious Diseases*. 2020.
9. Aroch I, Ofri R, Sutton GA. Ocular Manifestations of Systemic Diseases. *Slatter's Fundamentals of Veterinary Ophthalmology*. 2008; 374-418.
10. Kwon-Chung KJ. Taxonomy of fungi causing mucormycosis and entomophthoromycosis (zygomycosis) and nomenclature of the disease: molecular mycologic perspectives. *Clin Infect Dis*. 2012; 54: 8-15.
11. Feng YH, Guo WW, Wang YR, Shi WX, Liu C, Li DM, et al. Rhinocerebral mucormycosis caused by *Rhizopus oryzae* in a patient with acute myeloid leukemia: A case report. *World J Dermatol*. 2020; 8(1): 1-9.
12. Walaa F. Antibiotic Drugs and Multidrug Resistance Bacteria. *Int J Pub Health Safe*. 2017; 2(131): 1-3
13. Spellberg B. Gastrointestinal mucormycosis: an evolving disease. *Gastroenterol Hepatol (N Y)*. 2012; 8(2): 140-2.
14. Ibrahim A, Spellberg B, Walsh T, Kontoyiannis DP. Pathogenesis of mucormycosis. *Clin Infect Dis*. 2012; 54: 16-22.
15. Challa S. Mucormycosis: Pathogenesis and Pathology. *Curr Fungal Infect Rep*. 2019; 13: 11-20.
16. Skiada A, Lass-Floerl C, Klimko N, Ibrahim A, Roilides E, Petrikos G. Challenges in the diagnosis and treatment of mucormycosis. *Med Mycol*. 2018; 56: 93-101.
17. Anna S, Ioannis P, Maria D. Epidemiology and Diagnosis of Mucormycosis: An Update. *J. Fungi*. 2020; 265.

18. Natesan SK, Chandrasekar PH. Isavuconazole for the treatment of invasive aspergillosis and mucormycosis: current evidence, safety, efficacy, and clinical recommendations. *Infect Drug Resist.* 2016; 9: 291-300.
19. Cascella M, Rajnik M, Aleem A, et al. Features, Evaluation, and Treatment of Coronavirus (COVID-19) [Updated 2021 Apr 20]. In: StatPearls [Internet]. Treasure Island (FL): StatPearls Publishing; 2021.
20. Hu K, Patel J, Swiston C, et al. Ophthalmic Manifestations of Coronavirus (COVID-19) [Updated 2021 May 19]. In: StatPearls [Internet]. Treasure Island (FL): StatPearls.