

Clinical Experience of Small Incision-Assisted Encor System in Resection of Large Breast Tumors

Zhu G[#], Wu NY[#], He SM¹, Qiu C¹, Zeng ZQ², Zhang YF⁴, Li Q¹ and Zhou D^{3*}

¹Department of Breast, Nanhai Mathernity & Child Healthcare Hospital, Nanhai District, Foshan, Guangdong, China

²Breast Department of General Surgery Hospital, Foshan Fusun Chancheng Hospital, Foshan, Guangdong, China

³Department of Breast Surgery, The First People's Hospital of Foshan, Foshan, Guangdong, China

⁴Department of Breast Cancer, Guang Dong General Hospital, Guangdong Academy of Medical Sciences, Guangzhou, China

[#]These authors contributed equally to this work and should be considered co-first authors .

*Corresponding author:

Dan Zhou,
Department of Breast Surgery, The First People's
Hospital of Foshan, Foshan, Guangdong, China,
E-mail: Zdan14@fsyyy.com

Received: 06 Sep 2022

Accepted: 15 Sep 2022

Published: 20 Sep 2022

J Short Name: COO

Copyright:

©2022 Zhu G, This is an open access article distributed under the terms of the Creative Commons Attribution License, which permits unrestricted use, distribution, and build upon your work non-commercially, E-mail: gq2000cncn@outlook.com

Citation:

Zhu G and Wu NY. Clinical Experience of Small Incision-Assisted Encor System in Resection of Large Breast Tumors . Clin Onco. 2022; 6(11): 1-6

Keywords:

EnCor vacuum assisted breast biopsy system, small incision, ultrasound guidance, benign breast tumor

1. Abstract

1.1. Objective: to investigate the application value of small incision-assisted EnCor vacuum-assisted breast biopsy (VAB) system under the guidance of ultrasound in minimally invasive rotary resection of large benign breast tumors. Method: from November 2012 to July 2021, minimally invasive rotary resection with small incision-assisted ultrasound-guided EnCor system was conducted on 59 large benign breast tumors out of 51 cases. Among these resected tumors, there were 23 tumors with the largest diameter of 30-39mm, 17 tumors with 40-49mm, 10 tumors with 50-59mm, and 9 tumors with 60-100mm. Results: from November 2012 to July 2021, minimally invasive rotary resection with small incision-assisted ultrasound-guided EnCor system was conducted on 51 out of 59 cases with large benign breast tumors. Among these resected tumors, there were 23 tumors with the largest diameter of 30-39mm, 17 tumors with 40-49mm, 10 tumors with 50-59mm, and 9 tumors with 60-100mm. There were no other complications observed except for 2 and 3 cases of subcutaneous congestion and local depression respectively. All patients were followed up for 3 to 56 months with regular ultrasound examination, and no local recurrence was observed. Conclusion: using the EnCor vacuum-assisted breast biopsy (VAB) system in the minimally invasive rotary resection of large benign breast tumors, the lesions can be completely removed with smaller scars and few complications. The simplicity and effectiveness make it easy to popularize.

It has been more than 20 years since the Mammotome system was invented in 1995, symbolizing the birth of the vacuum assisted biopsy (VAB) system, and was approved by the FDA for the resection of small breast lesions in 2004. Since introduced into China for clinical application, it has gradually become one of the most standard breast surgery methods because of its advantages of locating lesions and preserving the physical appearance. Reviewing relevant literature (e.g. PubMed, CNKI), using "Mammotome", "Rotary resection", "vacuum assisted breast biopsy" as search keywords, most of the results are discussions on resection of small tumors or untouchable lesions. Generally, minimally invasive rotary excision surgery targets at tumors with diameters less than or equal to 3cm. However, in the era when endoscopic technology has enabled minimally invasive treatment for almost all open operations, treating benign breast tumors larger than 3cm with existing equipments and technologies remains a challenge. Since the introduction of the EnCor vacuum-assisted breast biopsy (VAB) system in 2010, our department has made bold attempts in this challenge since 2012 after mastering the general technique of breast lesion resection. From the very beginning, we could only perform small incision-assisted VAB surgery according to the principle of hand-assisted laparoscopic surgery. Until now, we gradually mastered the technology and applied it to larger and larger tumors, acquiring satisfactory feedbacks from patients in postoperative follow up tracking. We summarize past cases in the last 8 years in this

paper and hope to inspire and make progress with colleagues who are interested in clinical surgery of large benign breast tumors.

2. Clinical Materials and Methods

2.1. Generic Materials

Inspired by the hand-assisted laparoscopy that removes the specimens from the abdominal cavity through the small incision during the surgery, a small incision is made in the hidden parts such as the edge of the areola or the outer side of the breast. After excising the majority of the tumor tissue with the VAB system, the collapsed tumor capsule and other tissues are taken out from the auxiliary incision that is larger than the VAB one. We can achieve the purpose of keeping the organ's beauty when treating large breast tumors through combining VAB with traditional manipulation. There are 51 cases of small incision-assisted minimally invasive surgery for large breast tumors in our department from November 2012 to July 2021. All the patients are female aged from 10 to 59 years old, with the median of 29 years old. There are 59 palpable large tumors and we merge more than 70 lesions with diameter 5-29mm. Preoperative ultrasound shows 59 large tumors, of which 23 are of maximum diameter 30-39mm, 17 are 40-49mm, 10 are 50-59mm, 4 are 60-69mm, and 2 are 70-79mm, 1 is 80-89mm and 2 are 90-100mm. According to the medical history, preoperative physical examination, ultrasound and mammography, the 59 lesions in this group are all substantial, the preoperative ultrasound BI-RADS grades are all 2-4, and mammography BI-RADS grades are all II-III. For suspicious tumors and tumors larger than 5cm, CNB biopsy and frozen section are recommended. The pathological results are all fibroadenoma, and the gross pathologies of 2 cases are benign phyllodes tumor. Case selection criteria: at least one breast tumor with a diameter larger than or equal to 35mm, clinical and imaging assessment as benign breast tumor, suspicious CNB biopsy as benign tumor.

2.2. Method

2.2.1. Equipment: American EnCor vacuum-assisted breast biopsy system, Mammotome Revolve vacuum-assisted breast biopsy system is used in the later part. It consists of rotary cutter (i.e., breast biopsy needle), vacuum negative pressure system, (handle and foot pedal) controller and related software. 7G rotary cutter is used in this group of cases. B-ultrasound is performed using a Terason T2000 high-frequency ultrasound machine with a probe frequency of 7-12 MHz, and a Konica Minolta SONIMAGE HS1 ultrasound machine is used later.

2.2.2. Instruction: Verify that the VAB system is functioning properly. Anesthesia: local anesthesia or intravenous general anesthesia can be used, depending on the number and size of the lesions. The patient lies supine, the upper extremities are abducted, the drape is routinely sterilized, an incision is made at the edge of the areola (or the edge of the breast), the skin is incised with a scalpel about 1-2 cm, and the glandular tissue of the breast is separated to reach the

surface of the tumor. Bluntly dissociate the tumor along the tumor capsule until the tumor is completely free, insert the rotary biopsy knife into the tumor tissue from the incision, adjust the rotary knife groove so that it is located in the tumor capsule, and display the whole process under the ultrasound image, repeat the rotary cutting several times until the ultrasound shows that the tumor tissue resection volume is sufficient, the tumor collapses and the volume is reduced, terminate the rotary cutting, withdraw the rotary cutter, clamp the tumor capsule and part of the fluid tissue, and remove the collapsed tumor together with its surrounding tissue. Initially, surgeons are entangled with the completeness of the capsule, focusing on the integration of the capsule. In recent years, it is advisable to pay attention to the complete removal of all tumor tissues and capsules after debulking, without insisting on integral removal. The key is to repeat palpation and ultrasound examination before the end of the operation, and be careful not to have residual tumor tissue. Clean up the residual cavity, inject 1: 200,000 epinephrine saline (more recently bacitretin 4u/100ml 0.9% NS) into the residual cavity to stop bleeding, retain the saline for 5 minutes, compress the tumor cavity, suture the small incision, and wrap it with elastic bandages. If there are multiple lesions, insert the EnCor rotary biopsy knife from the small incision, and reach the bottom of lesion in each quadrant under the guidance of ultrasound and conduct the routine minimally invasive rotary resection.

3. Results

In 51 cases, 59 large tumor lesions and corresponding medium and small lesions were removed in 51 cases. There were 28 cases with a single lesion, 14 cases with 2-3 lesions, 5 cases with 4-5 lesions, and 4 cases with more than 6 lesions. The average operation time was 86.8 minutes (40-255 minutes). 1 case had 8 bilateral lesions and 4 large tumors (maximum diameter of 30-52 mm), and the operation time was 255 minutes; 1 case had 3 lesions in the right breast, of which the maximum diameter of the large tumor was 88mm and the maximum diameter of the two combined lesions were 29mm and 23mm, and the surgery took 245 minutes. It took 40 minutes in 3 cases, where 2 cases with single lesion, the maximum diameter of the tumor is 39mm and 50mm, and 1 case with a maximum diameter of 43mm and 1 combined lesion with a maximum diameter of 6mm.

Short-term postoperative complications: 2 cases of subcutaneous congestion, 3 cases of local depression, no infection or wound dehiscence occurred. The scar is 1.0-1.2 cm long, concealed and beautiful. The pathological diagnoses were all benign lesions: 44 cases of breast fibroadenoma, 1 case of giant fibroadenoma, 1 case of juvenile fibroadenoma, 1 case of tuberous sclerosis breast disease, 3 cases of benign phyllodes tumor and 1 case of tumor. There were 2 cases of subcutaneous congestion after operation, both of which were multiple tumor cases and was absorbed after 3 months. 3 cases had skin depression at the wound cavity, and the depression disappeared 3 and 6 months after operation and the shape of the

breast remained the same. All patients were followed up for 3 to 56 months, receiving clinical physical examination and ultrasonography. One case of multiple fibroadenomas had recurrent multiple fibroadenomas in the third year after operation, and the second op-

eration was required. Ultrasound showed hypoechoic foci in 4 cases, which were not palpable by clinical physical examination. The imaging review was performed. One patient with 50mm solitary fibroadenoma had smooth breastfeeding 4 years after operation, and there was no difference in bilateral breastfeeding.

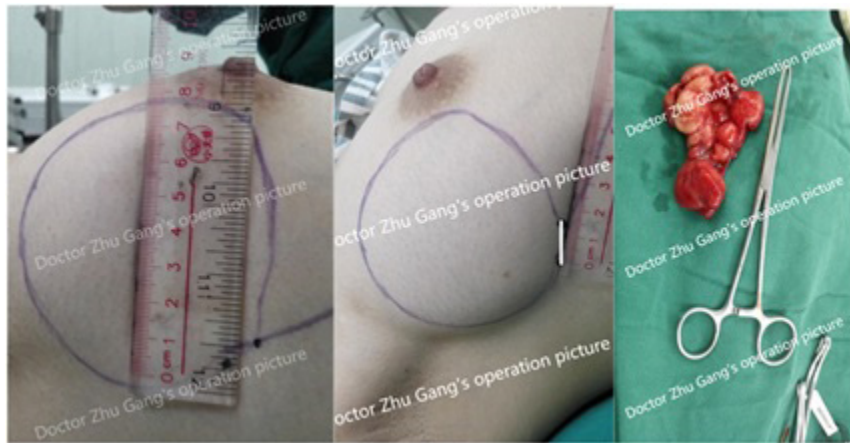


Figure 1: The tumor is about 8cm in diameter. Select the outer edge as the incision, about 1.5cm long. Reduced volume tumor with relatively integral capsule.

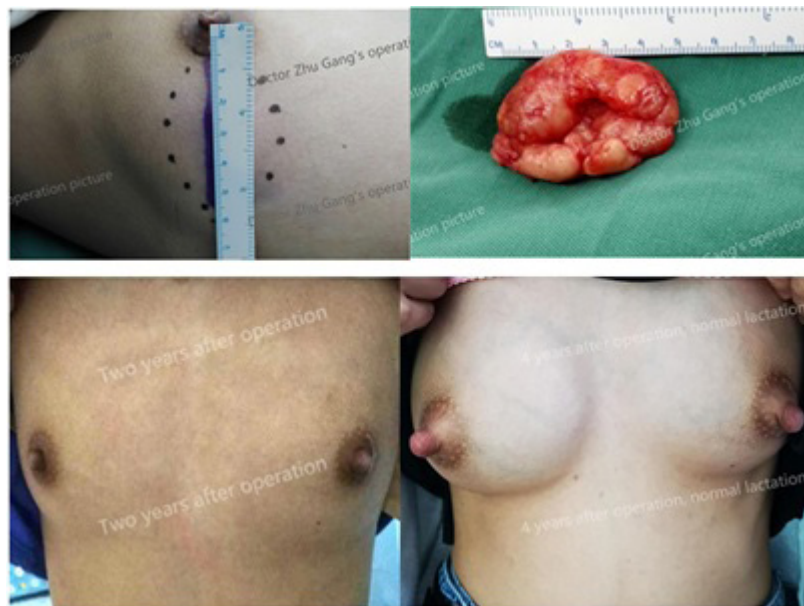

Figure 2: 20-year-old, 5cm fibroadenoma surgery (top left and right), follow-up 2 years after surgery (bottom left), and normal breastfeeding 4 years after surgery (bottom right)

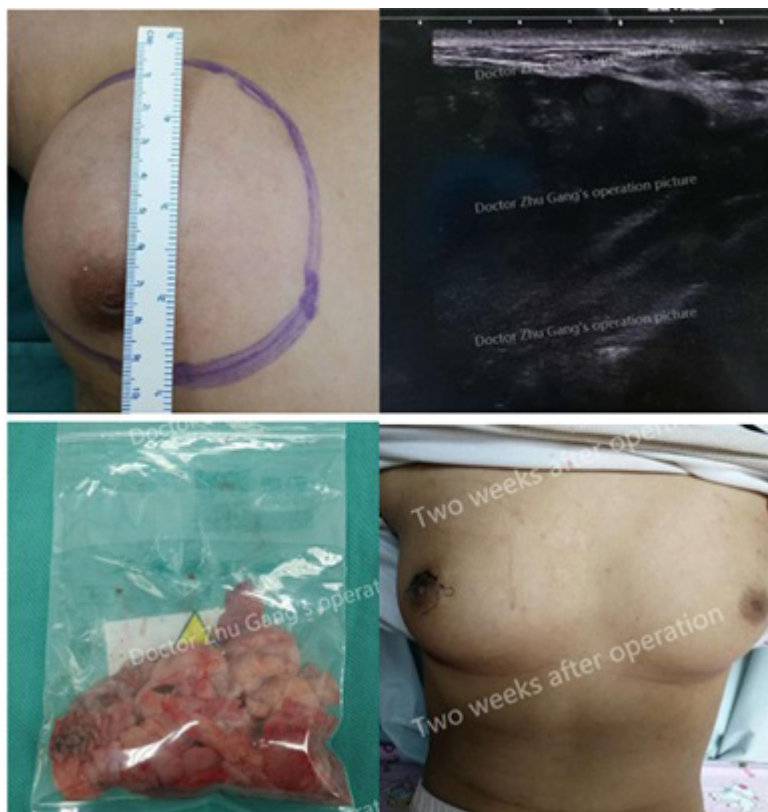

Figure 3: 10-year-old child with 10cm juvenile fibroadenoma surgery and 2-week postoperative photos

4. Discussion

In the treatment of solid breast tumors, surgical resection is the first choice. With the advent of the era of minimally invasive surgery and the continuous improvement of women's requirements for breast function and aesthetics, how to achieve satisfactory treatment while maintaining good breast appearance and function has become the future direction of benign breast tumor surgical treatment. The "Consensus on the Diagnosis and Treatment of Breast Fibroadenomas" promulgated in 2014 by the Breast Health and Disease Prevention and Treatment Group of the Women's Health Branch of the Chinese Preventive Medicine Association pointed out that: 1. Incisional tumor resection is an intuitive and effective treatment method, but with poor aesthetics. It is suitable for patients with large fibroadenomas > 3cm or patients who are suitable for incision according to the judgment of the doctor. 2. Vacuum-assisted hollow needle (surgery), minimally invasive rotary resection, which can be performed under the guidance of ultrasound or molybdenum and palladium, has the characteristics of less trauma and little impact on appearance, and is a safe, effective and well-tolerated treatment method. This method is suitable for patients whose fibroadenoma diameter \leq 3cm. How can a large number of benign breast tumors larger than 3 cm (mainly larger fibroadenomas) be minimally invasively resected while maintaining aesthetics? In our work, we explored an eclectic but efficient surgical method with satisfactory results. The technical characteristics are summarized as follows:

First of all, we make full use of the characteristics of areola pig-

ment and skin folds on the breast edge during the operation, and make a small incision of about 1-2cm along the arc of the areola and the edge of the breast (Figure 1) (the minimum incision is 1.5 cm, and can be 1 cm in suitable cases when sufficiently skilled). The wound of postoperative intradermal suture is small and hidden, and the scar is concealed. Then, fibroadenoma is active for its complete capsule. Therefore, blunt dissection is performed close to the tumor capsule, and the damage to the normal glands around the tumor is reduced to a minimum. The operation has less bleeding and less damage to the surrounding glands so as the milk ducts in the glands. A patient (Figure 2) with a 5cm large fibroadenoma in this group was able to breastfeed normally after 4 years of resection with small incision-assisted atherectomy, which justifies the author's perspective. Next, the EnCor rotary resecting system is used to cut the cavity from the inside of the tumor, so that the volume of the large tumor can be reduced, and the tumor capsule and part of the tumor tissue can be completely removed through a small incision. In this group of cases, 14 cases had tumors with a maximum diameter of 5.0-6.9cm, and 5 cases were 7-10cm. Compared with the traditional open surgery method, the surgical incision is greatly reduced, and the incision on the breast surface skin is avoided. A 1.5-2cm incision is made on insignificant position like the areola and the edge of the breast. After the wound is healed by intradermal suture, the scar is small and hidden, which can meet the aesthetic requirements of patients with large breast tumors to the greatest extent. Finally, compared with the minimally invasive rotary resection completely using the EnCor system, our approach has the following advantages: first, the tumor capsule is preserved

during the operation, which reduces the risk of residual tumor through sequentially clamping out the capsule and volume-reduced tumor tissues in late operative stage. Second, our approach reduces the working time of the rotary cutting equipment, improves the efficiency of the operation, and reduces the risk of excessive use of the EnCor biopsy (rotation) needle, causing blockage of the pipeline and increasing the cost of biopsy tools. We searched relevant literature on minimally invasive rotary resection (i.e., VAB surgery) and found that the largest breast tumor was a 6.2cm one reported by Lihua Cheng et al. from Changzhou No.2 People's Hospital [8]. Since the tumor is three-dimensional, the resection volume of rotational surgery grows cubically with the increase of tumor's radius, which is time-consuming, labor-intensive and equipment-intensive. It is hard to imagine how long it would take to resect giant fibroadenomas up to 8-10 cm in diameter by pure VAB surgery. Third, most of the sharp incision is performed within the tumor capsule, which reduces the damage to the surrounding normal glands and milk ducts. Compared with complete VAB surgery, it is more likely to preserve the breastfeeding function after surgery for large tumor patients. Compared with existing approaches like the use of uterine cutter [1] and laparoscopic surgery [2, 3], submammary fold incision [4, 5], areola arc incision [6], and "Z" shape excision of giant breast fibroadenoma [7], our method has the advantages of simplifying surgical operation, reducing trauma, small and concealed scars, basically symmetrical bilateral breasts after surgery, and no need for mammary glands reconstruction. When writing this article, we checked the relevant literature and found that the operation method was quite consistent with that described in the article published by Lihua Cheng [8] in 2015. It reported that 19 small incisions of 2-6.2cm combined with rotary body reduction were followed up for 1-3 months, and no recurrence was found. Wang T, Zhu L [9] according to the case report published in 2020, a 6x6cm juvenile giant fibroadenoma was also treated with small incision combined with VAB. After 2 years of follow-up, the cosmetic effect was good and no recurrence was found. In our study, the tumor size and number were more abundant, and the postoperative follow-up time was longer. Because there were more than 2 lesions in 23 cases (45.1%), and large tumor (diameter larger than 5cm) in 19 cases (37.3%), it took longer than usual. However, after the technique is proficient, the operation time for a single tumor of 4-5 cm is about 40 minutes. Bo Yang, Hong Wang, Jujiang Guo and other teams have independently conducted clinical research on the resection of large benign breast masses by Mammotome atherectomy [10-12], consistently concluding that pure VAB surgery has no obvious advantage over traditional open surgery on total operation time, intraoperative blood loss and postoperative complications in the treatment of large benign breast tumors. Its biggest advantage is that the incision length is short, and there are no or only small scar after operation, which is unmatched by the traditional surgery. Postoperative intramammary hematoma, surgical area infection, skin de-

pression, and breast appearance deformity are common complications after surgical treatment of breast tumors, which are basically the same as those of open surgery. Skin depression after VAB surgery is mostly due to the fact that the tumor is close to the skin, and the subcutaneous fat is removed by rotary cutting, rather than tissue defects caused by resecting the huge tumor. No matter how big the tumor is, it is external, and the bilateral breasts can only be symmetrical after removal of the tumors. Since the small incision-assisted VAB technique used in this paper conducts blunt dissociation outside the tumor capsule and the VAB operation is basically performed inside the capsule, whose inherent advantages are that the surrounding tissues such as subcutaneous fat and milk ducts will not or rarely be removed. In addition, groups and individuals are getting more and more opportunities screening due to the increasingly popularity of breast cancer screening. In addition to palpable larger tumors, patients with combined multiple impalpable breast nodules are clinically common. The proportion of patients with more than one lesion was as high as 45.1% in this group. The larger tumor has been paid attention to and examined in many ways (CNB biopsy is recommended for patients with large tumors before operation), and the final results are all benign (including benign phyllodes tumor). For the lesions, open surgery cannot accurately remove the remaining 3 impalpable lesions, but combined with ultrasound-guided VAB technology, after all lesions were removed and sent for inspection, the pathology reported that one of the small nodules had local ductal dysplasia. That is, VAB surgery removes the precancerous lesions. The author believes that this is one of the clear advantages of VAB surgery over traditional surgery, not just in terms of aesthetics. Before the publication of this article, we checked the relevant literature and found that this group of cases is the first report of the application of VAB technology in the resection of 10cm huge breast tumors (Figure 3) at homeland abroad, and it is also the first report of normal lactation cases after minimally invasive rotary resection of large tumors. The above cases have ID number, hospitalization number, pathological report, photos and other detailed information for inquiry. In addition, the selection of cases requires not only large tumors, but also the clinical diagnosis of benign lesions, and patients need to accept minimally invasive rotary resection (patients and their families will be worried about residues), as well as the corresponding increase in economic expenditures and many other factors. The summary of this group of cases lasted for more than 8 years, which also gave the author the opportunity to follow up and review for a long time. Different from the above-mentioned general review time of 1-12 months, we can review at the rhythm of 3-6 months after normal minimally invasive rotary resection, accumulating subjective and objective materials such as outpatient ultrasound and photos. Thanks to the sufficient time, even a patient with a maximum of 5 cm and 6 lesions on the same side underwent surgery and participated in the video recording of surgery. Therefore, the medical records collected in this paper are relatively sub-

stantial, and the problems of long-term postoperative complications and tumor recurrence are also considered.

In addition, the selection of cases requires not only large tumors, but also the clinical diagnosis of benign lesions, and patients need to accept minimally invasive rotary resection (patients and their families will be worried about residues), as well as the corresponding increase in economic expenditures and many other factors. The summary of this group of cases lasted for more than 8 years, which also gave the author the opportunity to follow up and review for a long time. Different from the above-mentioned general review time of 1-12 months, we can review at the rhythm of 3-6 months after normal minimally invasive atherectomy, accumulating subjective and objective materials such as outpatient ultrasound and photos. Thanks to the sufficient time, even a patient with a maximum of 5 cm and 6 lesions on the same side underwent surgery and participated in the video recording of surgery. Therefore, the medical records collected in this paper are relatively substantial, and the problems of long-term postoperative complications and tumor recurrence are also considered.

At present, VAB systems such as EnCor and Mammotome are quite popular in China. They provide a simple and easy surgical solution for the minimally invasive rotary resection of large benign breast tumors. In the department where the author works at, 60% of the doctors can independently carry out such operations. We are willing to discuss with those who are interested in benign large breast tumor surgery to better serve patients.

5. Declarations

5.1. Ethical Approval

This article is a retrospective article, which has been approved by the ethics committee of the unit, and has uploaded a scanned document.

5.2. Competing interests

The authors declare that there are no financial or personal nature conflicts of interest

References

- Jing Zhu, Dajiang Zhu, Zhaoxuan Guo, et al. Circle excision with small incision for giant breast fibroadenoma: report of 11 cases[J/CD]. Chinese Journal of Breast Disease (Electronic Edition). 2010; 4(2): 218-222.
- Chengyu Luo, Lei Xue, Hua Lin, et. al. Mastoscopic extirpation of benign breast masses by small and concealing incision. National Medical Journal of China. 2003; 83(14): 1233-1235.
- Ningwen Tang, wai qian fa qiang jing fu zhu you ru ju xian wei xian liu qie chu shu 1 li, Chinese Journal of Breast Disease (Electronic Edition). 2008; 2(3): 367-368.
- Zhengxuan Niu, Yunwen Yan, Jingjie Zhang, et. al. Treatment of adolescent breast fibroadenoma by submammary fold incision, Chinese Journal of Aesthetic Medicine. 2009; 18(11): 1585-1586.
- Xuening Shi. Improvement of cosmetic incision in the treatment of benign breast tumors in juveniles: report of 10 cases, The Journal of Medical Theory and Practice. 2011; 24(2): 178-179
- Zhenting Yang. Improvement of surgery for giant breast fibroadenomas, Jiangsu Medical Journal. 1991; 6: 26.
- Aiqiang Feng, Ju Wang. "Z" shape resection of giant breast fibroadenomas: a report of 21 cases, Chinese Journal of General Surgery. 2012; 21(11): 1481-1483.
- Lihua Cheng, Yulan Zhu, Lingyun Xu, et al. Small incision combined ultrasound-guided body augmentation in treating breast fibroadenoma, Journal of Qiqihar University of Medicine. 2015; (21): 3170-3172.
- Wang T, Zhu L. Mammotome-assisted removal with minimal incision of large juvenile fibroadenoma of breast: A case report. Medicine. 2020; 99: 10(e19442).
- Juli Lin, Zhanlin Zhu, Hehui Mao, et al., Analysis of the effect and complications of Mammotome minimally invasive surgery in the treatment of large breast tumors, Maternal & Child Health Care of China. 2018; 33(9): 2143-2146.
- Bo Yang, Shi Tang, Yuehuan Yuan, et al. Resection of large benign breast tumor with ultrasound-guided Mammotome revolve device, Chinese Journal of General Surgery. 2015; 24(5): 683-686.
- Liudan Li, Hong Wang. Comparison of short-term curative effects of ultrasound-guided Mammotome biopsy and traditional open resection in treatment of relatively large benign breast tumors, China Medicine and Pharmacy. 2020; 10(5): 219-221.