

## Cutaneous Toxicity Associated with Ribociclib in a Patient with Metastatic Hormone Receptor-Positive Breast Cancer: A Case Report

Giannecchini GV<sup>1\*</sup>, Bretas GO<sup>1</sup>, Neves EKPB<sup>1</sup>, Amorim AGF<sup>2</sup>, Fernandes MM<sup>3</sup>, Lima LHSD<sup>1,4</sup> and Gonçalves AC<sup>1</sup>

<sup>1</sup>Oncoclínicas, Brazil

<sup>2</sup>Dermatologist by Universidade Federal Fluminense (UFF), Member of the Brazilian Society of Dermatology, Specialist in Laser, Cosmiatry, and Dermatological Procedures by Albert Einstein Hospital, São Paulo, Brazil

<sup>3</sup>Breast Surgeon, Member of Brazilian Society of Mastology, Brazil

<sup>4</sup>Federal Hospital of Ipanema, Rio de Janeiro, Brazil

### \*Corresponding author:

Giovanna Vieira Giannecchini,  
Oncoclínicas, Praia de Botafogo, nº 300. Botafogo.  
Rio de Janeiro (RJ), Brazil

Received: 07 Oct 2023

Accepted: 20 Nov 2023

Published: 26 Nov 2023

J Short Name: COO

### Copyright:

©2023 Giannecchini GV, This is an open access article distributed under the terms of the Creative Commons Attribution License, which permits unrestricted use, distribution, and build upon your work non-commercially.

### Citation:

Giannecchini GV, Cutaneous Toxicity Associated with Ribociclib in a Patient with Metastatic Hormone Receptor-Positive Breast Cancer: A Case Report. Clin Onco.2023; 7(6): 1-4

### Keywords:

Advanced breast cancer; Cyclin-dependent kinase 4/6 inhibitors; Ribociclib; Cutaneous toxicity

### Abstract

In advanced hormone receptor-positive and human epidermal growth factor receptor 2 (HER2) negative breast cancer, cyclin-dependent kinase 4/6 (CDK4/6) inhibitors in combination with endocrine therapy improved progression-free survival over endocrine treatment and became the standard of care in the first-line setting. However, the incorporation of CDK4/6 inhibitors is recent, so we are still learning about the adverse events that may derive from using this class of drugs, including skin toxicity and dermatological reactions. We present a case of a 32-year-old patient recently diagnosed with metastatic breast cancer hormone receptor-positive, HER2-negative, that presented grade 4 cutaneous toxicity with ribociclib, a cyclin-dependent kinase 4/6 inhibitor.

### 1. Introduction

Breast cancer is the most frequent malignancy in women worldwide. It is a heterogeneous disease classified into three major subtypes: hormone receptor-positive/human epidermal growth factor receptor 2 (HER2) negative, HER2-positive, and triple negative. The first subtype is the most prevalent, occurring in 70% of patients [1].

Cyclin-dependent kinases 4 and 6 (CDK4/6) are essential in cell cycle regulation. They bind to D-type cyclins and then phosphorylate the tumor suppressor retinoblastoma protein (RB1), allowing cellular transition from G1 to S phase [2]. In hormone receptor (HR)-positive breast cancer, estrogen induces expression of cyclin D1 and consequently promotes CDK4/6 activity, leading to hyperphosphorylation of RB1 and cell cycle progression [3]. That is why the inhibition of CDK4/6 is an essential target in this breast cancer subtype.

Three oral CDK4/6 inhibitors are approved for HR-positive and HER2-negative metastatic breast cancer – palbociclib, ribociclib, and abemaciclib. Their use in combination with endocrine therapy in first-line treatment was evaluated in the pivotal phase 3 trials PALOMA-2, MONALEESA-2/MONALEESA-3/MONALEESA-7, and MONARCH-3, respectively [4-8]. All demonstrated statistically significant gains in progression-free survival (PFS), with ribociclib and abemaciclib also showing statistically significant improvements in overall survival (OS).

They represented a practice change in breast oncology. In women with advanced breast cancer HR-positive/HER2-negative, its combination with endocrine therapy is the preferred upfront treatment for most patients (chemotherapy still is the treatment of choice in patients with visceral crisis). The association of these drugs with some potential toxicities is well established, such as neutropenia with palbociclib and ribociclib, whereas diarrhea is

expected in the case of abemaciclib [9]. However, the use of this class is progressively increasing, and emerging adverse events are being described, such as cutaneous toxicities.

Here, we describe the case of a female patient who developed grade 4 cutaneous toxicity while treated with ribociclib.

## 2. Case Report

A 32-year-old patient with a history of endometriosis, without other comorbidities, noticed a nodule growth in the right breast. She began the investigation in February 2023, and a breast ultrasound showed a nodule in the right breast, estimated at 45 x 18 x 40 mm, with right axillary lymph node enlargement. Submitted to biopsy in the same month, which confirmed invasive carcinoma of the right breast of the non-special type, grade 2. By immunohistochemistry, progesterone receptor Allred 8, and estrogen receptor Allred 8, Ki67 20%, and HER2 negative (score 0). On clinical examination, the patient had an 8-cm lesion in the right breast, without skin involvement, and a palpable 3-cm lymph node enlargement in the right armpit. Initially, she was referred by the breast surgeon for evaluation regarding neoadjuvant treatment, with the first consultation with a clinical oncologist in March 2023. However, suspicious hepatic nodules for secondary involvement were described in CT scans for staging. She was then submitted to PET-CT with evidence of metastatic disease to the liver and lymph nodes. Therefore, she started first-line treatment with ribociclib associated with letrozole and goserelin. The genetic panel was performed by Next Generation Sequencing (NGS), without detection of pathogenic variants.

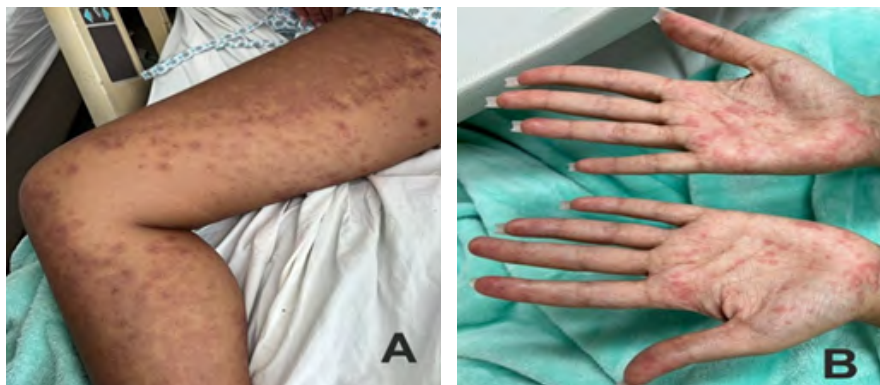
In the third week of treatment, a few erythematous cutaneous lesions appeared as skin rash, distributed asymmetrically on the body, especially on hands and feet. A corticosteroid ointment was prescribed, but there was no improvement in the skin condition, so a referral was made to dermatology. The medical team advised temporarily discontinuing ribociclib. However, despite this recommendation, the patient continued taking the cyclin inhibitor, leading to a significant worsening of the dermatological lesions, now presenting erythematous-violaceous target plaques, some of them confluent, ponphobic, and some with hemorrhagic crusts, including lesions in palms, without cutaneous blisters or mucosal

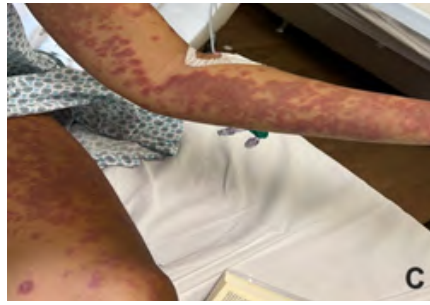involvement (Figure 1).

The patient reported symptoms of headache, body pain, and fever. Despite the strong suspicion of pharmacodermia, urgent examinations were requested to rule out the coexistence of an infectious condition. Oral treatment with ribociclib and letrozole was discontinued. It was then started prednisone 1mg/kg and hydroxyzine. After 48 hours of high-dose corticosteroid therapy, there was the appearance of periorificial nasal lesions and worsening of body injuries and pruritus.

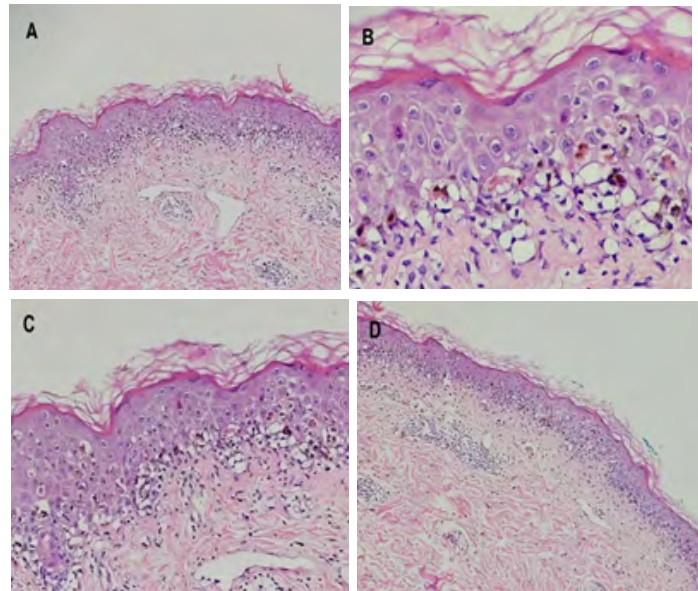
Given the clinical condition, the patient required hospitalization in May 2023. Initially, she was admitted to the intensive care unit due to the extent of the lesions. She was closely monitored by the dermatology department throughout the hospital stay and received high-dose intravenous corticosteroids. Additionally, a skin biopsy of the left knee was performed. Histological sections showed fragments of skin with acanthosis and hyperkeratosis, occasional apoptotic keratinocytes, and foci of vacuolar degeneration of the basal layer of the epidermis, while in the dermis superficial perivascular lymphomononuclear inflammatory infiltrate was observed (Figure 2). The histopathological report was consistent with erythema multiforme, an immune-mediated disorder caused by some infections (most commonly by herpes simplex virus infection) or medications [10].

The patient showed progressive improvement in the dermatological condition throughout the hospitalization and was discharged with oral antihistamine and oral corticosteroid (1mg/kg prednisone). Outpatient follow-up with a dermatologist was made for gradual tapering of the medication. In consultation with clinical oncology after discharge, the cutaneous lesions were healing, no longer pruritus, and with hyperchromic coloration (Figure 3). Given the suspicion of ribociclib-mediated cutaneous toxicity, it was decided to resume letrozole and permanently discontinue ribociclib. After one week of letrozole, the patient did not present any dermatological worsening and, therefore, abemaciclib was associated in replacement to ribociclib. The patient has shown good tolerance to this new combination, and no new cutaneous toxicity has been observed.

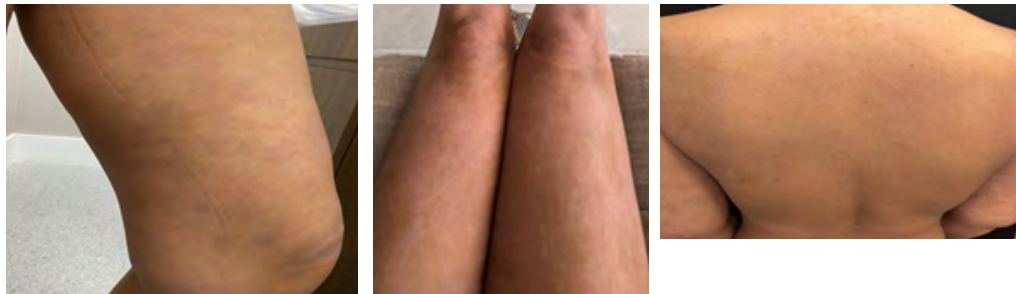




**Figure 1:** Cutaneous lesions characterized by erythematous-violaceous target plaques isolated and confluent in legs (A), palms (B), and diffusely by the lower and upper limbs (C)



**Figure 2:** Fragments of skin from biopsy of the left knee with acanthosis and hyperkeratosis (A), occasional apoptotic keratinocytes (B), and foci of vacuolar degeneration of the basal layer of the epidermis (C). Superficial perivascular lymphomononuclear inflammatory infiltrate observed in the dermis (D).



**Figure 3:** Clinical evolution of the lesions after hospitalization and treatment with corticosteroids.

### 3. Discussion

Palbociclib, ribociclib, and abemaciclib are currently approved CDK 4/6 inhibitors. They changed the prognosis of metastatic hormone receptor-positive/HER2-negative breast cancer by significantly improving PFS when combined with endocrine therapy compared to monotherapy with endocrine treatment [11]. Besides improving PFS, ribociclib and abemaciclib also improved OS in the metastatic setting.

There are no trials directly comparing the three CDK4/6 inhibitors, and the decision on which to prescribe is primarily based on the physician's choice and experience, safety profile, cost, or the United Prime Publications., <https://clinicosononcology.org/>

preference policy of the oncology clinic [12]. Although all three have the exact primary mechanism of action by interfering in cell cycle progression, there are pharmacological differences that are important to understand the distinct profile of adverse events and therefore help to select the most appropriate for each patient. CDK4 is essential for breast tumorigenesis, while CDK6 plays a role in hematopoietic stem cell differentiation [13]. Abemaciclib is structurally different from palbociclib and ribociclib; it is 14 times more potent against CDK4 than against CDK6 and inhibits multiple other kinases [11]. Therefore, hematologic adverse events are more common and severe with palbociclib and ribociclib,

whereas abemaciclib is more associated with diarrhea and fatigue [13].

When we focus on skin toxicities, alopecia is the most frequently reported event in pivotal trials, and it may be increased by nearly two-fold in comparison with endocrine monotherapy [14]. However, other cutaneous adverse events are being reported, such as dermal/epidermal conditions, hair and nail disorders, and serious bullous conditions, some even associated with considerable discontinuation rates [15].

#### 4. Conclusion

A growing incidence of adverse events has accompanied the increasing use of CDK4/6 inhibitors, some of them little described in pivotal studies, such as cutaneous events. In this context, we wrote this case report to elucidate the importance of early recognition and adequate management of possible cutaneous toxicities associated with cyclin inhibitors to avoid potentially serious complications.

#### References

1. Waks AG, Winer EP. Breast Cancer Treatment: A Review. *JAMA*. 2019; 321(3): 288-300.
2. Goel S, Bergholz JS, Zhao JJ. Targeting CDK4 and CDK6 in cancer. *Nat Rev Cancer*. 2022; 22(6): 356-72.
3. Spring LM, Wander SA, Andre F, Moy B, Turner NC, Bardia A. Cyclin-dependent kinase 4 and 6 inhibitors for hormone receptor-positive breast cancer: past, present, and future. *Lancet*. 2020; 395(10226): 817-27.
4. Finn RS, Martin M, Rugo HS, Jones S, Im SA, Gelmon K, et al. Palbociclib and Letrozole in Advanced Breast Cancer. *N Engl J Med*. 2016; 375(20): 1925-36.
5. Hortobagyi GN, Stemmer SM, Burris HA, Yap YS, Sonke GS, Paluch-Shimon S, et al. Ribociclib as First-Line Therapy for HR-Positive, Advanced Breast Cancer. *N Engl J Med*. 2016; 375(18): 1738-48.
6. Slamon DJ, Neven P, Chia S, Fasching PA, De Laurentiis M, Im SA, et al. Phase III Randomized Study of Ribociclib and Fulvestrant in Hormone Receptor-Positive, Human Epidermal Growth Factor Receptor 2-Negative Advanced Breast Cancer: MONALEESA-3. *J Clin Oncol*. 2018; 36(24): 2465-72.
7. Im SA, Lu YS, Bardia A, Harbeck N, Colleoni M, Franke F, et al. Overall Survival with Ribociclib plus Endocrine Therapy in Breast Cancer. *N Engl J Med*. 2019; 381(4): 307-16.
8. Goetz MP, Toi M, Campone M, Sohn J, Paluch-Shimon S, Huober J, et al. MONARCH 3: Abemaciclib as Initial Therapy for Advanced Breast Cancer. *J Clin Oncol*. 2017; 35(32): 3638-46.
9. Desnoyers A, Nadler MB, Kumar V, Saleh R, Amir E. Comparison of treatment-related adverse events of different Cyclin-dependent kinase 4/6 inhibitors in metastatic breast cancer: A network meta-analysis. *Cancer Treat Rev*. 2020; 90: 102086.
10. Sokumbi O, Wetter DA. Clinical features, diagnosis, and treatment of erythema multiforme: a review for the practicing dermatologist. *Int J Dermatol*. 2012; 51(8): 889-902.
11. George MA, Qureshi S, Omene C, Toppmeyer DL, Ganesan S. Clinical and Pharmacologic Differences of CDK4/6 Inhibitors in Breast Cancer. *Front Oncol*. 2021; 11: 693104.
12. Braal CL, Jongbloed EM, Wilting SM, Mathijssen RHJ, Koolen SLW, Jager A. Inhibiting CDK4/6 in Breast Cancer with Palbociclib, Ribociclib, and Abemaciclib: Similarities and Differences. *Drugs*. 2021; 81(3): 317-31.
13. Thill M, Schmidt M. Management of adverse events during cyclin-dependent kinase 4/6 (CDK4/6) inhibitor-based treatment in breast cancer. *Ther Adv Med Oncol*. 2018; 10: 1758835918793326.
14. Minta A, Rose L, Park C, Trovato S, Lustberg MB, Sudheendra PK, et al. Retrospective cohort study of CDK4/6-inhibitor-induced alopecia in patients with breast cancer. *Journal of Clinical Oncology* 41, no. 16\_suppl (June 01, 2023) e13083-e13083. 2023.
15. Raschi E, Fusaroli M, La Placa M, Ardizzoni A, Zamagni C, Poluzzi E, et al. Skin Toxicities with Cyclin-Dependent Kinase 4/6 Inhibitors in Breast Cancer: Signals from Disproportionality Analysis of the FDA Adverse Event Reporting System. *Am J Clin Dermatol*. 2022; 23(2): 247-55.