

# Hypoparathyroidism – Not Only after Strumectomy Unusual Presentations of the Rare Disease

Misiorowski W\*, Szatańska AL and Zgliczyński W

Department of Endocrinology, Medical Center for Postgraduate Education, WarsawBielanski Hospital, Ceglowska 80 str. 01-809 Warsaw, Poland

Volume 2 Issue 2- 2019

Received Date: 06 Nov 2019

Accepted Date: 05 Dec 2019

Published Date: 10 Dec 2019

## 1. Abstract

Hypoparathyroidism (HypoPT) is an endocrine disease with low calcium and inappropriately low (insufficient) circulating PTH levels. HypoPT may have an autoimmune pathogenesis, however, the most common causes of chronic HypoPT are iatrogenic: mostly thyroid or parathyroid surgery. Much less frequently HypoPT is caused by an extensive oncological procedures: external neck irradiation, e.g. in lymphoma or neck surgery e.g. because of larynx or upper throat cancer. Tetany is the most famous, spectacular symptom associated with hypoparathyroidism, however it occurs only in about 70% of cases of this rare disease and its occurrence is determined not so much by the absolute size of the fall in serum calcium, if the speed at which the decline occurred. Therefore tetany can easily occur as a result of a even mild hypocalcemia immediately after thyroid surgery. However in post-laryngectomy or post-radiotherapy damage of the parathyroid glands occurs gradually, initially manifested only as decreased PTH reserve in response to the decreasing serum calcium, eventually leading to hypocalcemia. Such chronic hypocalcemia is often well tolerated, and difficult to identify, which implies the need for systematic monitoring of calcemia, as well as the performance of diagnostic tests with the slightest clinical suspicion of hypoparathyroidism.

## 2. Introduction

Hypoparathyroidism (HypoPT) is an endocrine disease with low calcium and inappropriately low (insufficient) circulating PTH levels. It is a rare condition, designated as an orphan disease by the European Commission in January 2014 (EU/3/13/1210) ([http://www.ema.europa.eu/ema/index.jsp?curlZpages/medicines/human/orphans/2014/01/human\\_orphan\\_001301.jsp&midZWC0b01ac058001d12b](http://www.ema.europa.eu/ema/index.jsp?curlZpages/medicines/human/orphans/2014/01/human_orphan_001301.jsp&midZWC0b01ac058001d12b)) and the only major endocrine condition today, where the hormonal insufficiency is not treated commonly by substitution of the missing hormone (PTH) [1, 2]. HypoPT may have an autoimmune pathogenesis, and the cause is a mutation in the autoimmune regulator of endocrine function (AIRE) gene. There are also many other rare genetic conditions that can cause HypoPT either as part of a syndrome (e.g. Di-George syndrome) or as an isolated endocrinopathy [3-6]. However, the most common causes of chronic HypoPT are iatrogenic: mostly thyroid or parathyroid surgery [3,4,7,8,9]

Much less frequently HypoPT is caused by an extensive oncological procedures: external neck irradiation, e.g. in lymphoma or

neck surgery e.g. because of larynx or upper throat cancer. In this particular cases, the oncological nature of the disease itself focuses on the most of the attention (as well the patient as doctors), which often results in neglect of other health hazards. Moreover, potentially poor prognosis, poor quality of life, and short survival time additionally mask the problem. However, in individual patients cured from a cancer, unrecognized hypoparathyroidism can in the long term, significantly affect the health and quality of life [10].

Tetany is the most famous, spectacular symptom associated with hypoparathyroidism. It is often forgotten that it occurs only in about 70% of cases of this rare disease and its occurrence is determined not so much by the absolute size of the fall in serum calcium, if the speed at which the decline occurred. Therefore tetany can easily occur as a result of a even mild hypocalcemia immediately after thyroid surgery, but may never occur in autoimmune HypoPT or after neck irradiation.

## 3. Case 1

54-year-old male, at the age of 26 years treated for non-Hodgkin

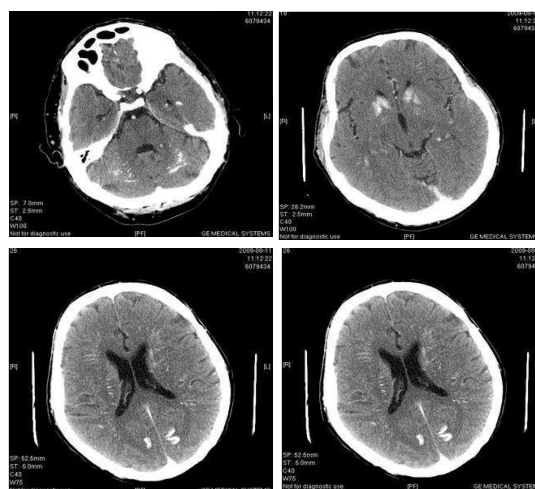
\*Corresponding Author (s): Waldemar Misiorowski, Department of Endocrinology, Medical Center for Postgraduate Education, WarsawBielanski Hospital, Ceglowska 80 str. 01-809 Warsaw, Poland, E-mail: w\_misiorowski@wp.pl

lymphoma with external irradiation of the neck and mediastinum, was repeatedly hospitalized because of attacks of dyspnoea with wheezing, resembling bronchial asthma. Because in provocation tests bronchial hyperresponsiveness has not been demonstrated, the symptoms were classified as psychosomatic, especially the patient connected their occurrence with the emotional stress or exercise. Moreover, the psychological study revealed abnormal personality of depressive and hypochondriacal type, with a significant social dysfunction, especially in the execution phase. Only accidentally made determination of serum calcium revealed severe hypocalcemia: 1.29 mmol/l. Patient was referred to the endocrinologist. Laboratory studies confirmed post-radiation hypoparathyroidism: serum Ca = 1.42 mmol/l; 24-hours urinary Ca = 0.93 mmol/24h; serum inorganic P = 1.61 mmol/l; serum PTH = 8.1 pg/ml. Post-radiation concomitant hypothyroidism also was diagnosed: TSH = 28.6 uIU/ml; FT4 = 8.75 pmol/l. After implementation of the treatment (alfacalcidol 1.25 µg per day + Calcium carbonate 2000 mg three times daily + L-thyroxine 100 µg/d) normalization of the biochemical indices was obtained and the patient's condition significantly improved: symptoms of bronchial smooth muscle contraction did not happen again, and the patient's mental state and ability to function in society was markedly improved.

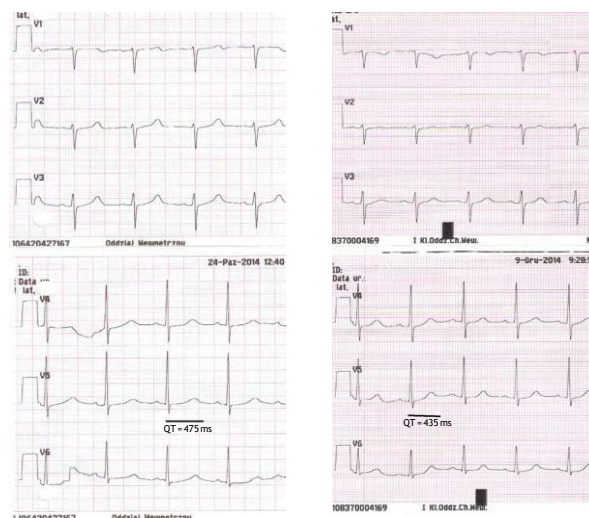
#### 4. Case 2

A 84-year-old male patient with tracheostomy resulting from the treatment of laryngeal cancer 30 years earlier, was admitted to the Department of Internal Medicine with a diagnosis of community-acquired, non-severe pneumonia of the right lung. Due to the very long period of time that had elapsed since surgery, we failed to get detailed information about the procedure. The patient denied a history of radiotherapy. The direct reason for hospitalization was loss of consciousness for several minutes while waiting for admission to a primary care physician. According to the patient's statement, he had been repeatedly experiencing similar episodes in the past few years, but did not report this problem to the doctor. Faintings occurred mostly in stressful situations, both in standing and sitting position, no relation to the effort, with no obvious convulsions, prodromal cardiovascular symptoms or urinary and fecal incontinence. After resolution of the infection we completed diagnostics of syncope. Laboratory studies revealed profound hypocalcemia: Ca = 1.31 mmol/L, ionized Ca = 0.73 mmol/L, hypocalciuria 24-h urinary Ca = 1.11 mmol/24h; hyperphosphatemia inorganic P = 1.49 mmol/L and low serum iPTH = 9.34 pg/mL. The diagnosis of hypoparathyroidism secondary to the past laryngectomy, was established. Symptoms and classical tetany signs (Chwostek's, Trousseau's) were negative, however other clinical features of long-standing hypocalcemia were found: electrocardiogram (ECG) prolongation of the QT

interval (corrected QT=475 milliseconds, **Figure 2**), and supraventricular and ventricular arrhythmias in 24-hours Holter ECG monitoring. The head CT revealed features of the extensive cerebral and cerebellum calcifications (like in Fahr's syndrome), however without of any neurological disorder, and electroencephalogram was within normal limits. Ophthalmic examination revealed bilateral cataracts. We also performed psychological tests, but due to the considerable difficulties in communicating with the patient (hearing loss, dysarthria) and also his advanced age, it was difficult to objectively assess the cognitive abilities. There was no obvious mental disorder, and the patient's functioning in everyday life was relatively satisfying. Oral replacement therapy of alfacalcidol 1 µg per day and calcium carbonate 1000 mg three times daily and was introduced. The control ECG showed normalization of the QT interval (corrected QT = 435 milliseconds, **Figure 2**). After two months of treatment we found the improvement of calcemia (2.13 mmol/l) and normalization of phosphates (1.11 mmol/l). The patient experienced a further overall improvement in well-being; no recurrent fainting was observed during 12-week-long follow-up.



**Figure.1** Extensive calcifications of the brain.



**Figure. 2** Patients' 3 ECG before (a) – and after the treatment (b).

## 5. Discussion

Hypocalcemia can present as an asymptomatic laboratory finding or as a severe, life-threatening condition. In the setting of acute hypocalcemia, rapid treatment may be necessary. In contrast, chronic hypocalcemia may be well tolerated, but treatment is necessary to prevent long-term complications. Patients with long-lasting, unrecognized HypoPT may develop neurological complications, including calcifications of the basal ganglia and other areas of the brain and extrapyramidal symptoms [11]. Grand mal, petit mal, or focal seizures have been described. Increased intracranial pressure and papilledema may be present [12,13]. If the patient has pre-existing subclinical epilepsy, hypocalcemia may lower the excitation threshold for seizures [12]. In some cases of chronic hypoparathyroidism, psychoses and organic brain syndrome have been noted [14]. Delayed development in children and the deterioration of intellectual and cognitive skills in adults, up to full dementia, is typical [15,16]. In the elderly population, disorientation or confusion also may be manifestations of hypocalcemia. Subnormal IQ, and poor cognitive function could also be a component of a syndrome that includes hypoparathyroidism as one of its features [15,16]. This is critically important to consider in young patients being evaluated for the condition. . Treatment of the hypocalcemia may improve mental functioning and personality, but amelioration of psychiatric symptoms is inconsistent. The typical tetany is rare, but changes in smooth muscle function with low serum levels of calcium may take the unusual form of dysphagia, abdominal pain, biliary colic, functional disturbances in urination or bronchospasm with wheezing, and dyspnea. Patients complain of constant or easy fatigue, emotional lability or anxiety. Typical is rapidly progressive subcapsular cataract [14].

Thyroid surgery is associated with hypocalcemia, presumably due to surgical disruption or vascular compromise of the parathyroid glands [9]. Transient hypocalcemia is observed in 16-55% of total thyroidectomy cases. One group recently reported that of the 50% of patients who developed post-operative hypocalcemia, hypoparathyroidism persisted beyond one month in 38% [16]. In another retrospective study, transient hypocalcemia was observed in 35% of patients undergoing total thyroidectomy, 3% had chronic hypocalcemia 6 months post-operatively, and 1.4% had permanent hypoparathyroidism 2 years post-operatively[17]. The type of surgery performed is associated with the risk of developing hypocalcemia. For example, risk of hypocalcemia is higher after total thyroidectomy with node dissection [9,18]. Transient hypocalcemia was observed more frequently after thyroidectomy for Graves' disease than for nontoxic multinodular goiter, although incidence of permanent hypoparathyroidism was not different between groups[19].

In patients undergoing laryngectomy or pharyngolaryngectomy for laryngeal carcinoma, complete or partial resection of the thyroid gland is often necessary. In least advanced cancers, at least mobilization of the thyroid gland with possible vascular disruption or ligation of the inferior thyroid artery or its branches is performed. That explain, why hypocalcemia is commonly observed after these procedures, however it is rarely recalled and unacknowledged issue. Basheeth et al. reported an incidence of biochemical hypocalcemia of 43% in laryngectomy patients observed up to the end of the first week after procedure; however, symptomatic hypocalcemia concerned only 15% of cases [20]. Concomitant bilateral neck dissection, previous treatment with radiotherapy and most probably also advanced T-classification of a tumor were significantly predictive of its appearance. What is interesting, no correlation between hypocalcemia and the extent of neither thyroidectomy, pharyngectomy, nor the presence of preoperative tracheostomy has been stated [20]. Especially little it is known about persistent hypocalcemia and parathyroid dysfunction in prospect of a few or even many years after surgery. Lo Galbo et al. reported 7.3% of persistent hypocalcaemia at 24 months after intervention in laryngectomy patients [21]. On the other hand, Thorp et el, in series of patients with laryngeal or pharyngolaryngeal cancer who lived 5 years after treatment, reported an incidence of hypoparathyroidism (with hypocalcemia or not) of over 60% in the subgroup subjected only to surgery [22]. It was shown that hypoparathyroidism occurred more commonly in patients who received radiotherapy either alone or in combination with surgery than in patients treated solely with surgery.

The irradiation of the neck region is a well-documented factor of delayed hypothyroidism, however the influence of radiotherapy on parathyroid glands is a poorly known phenomenon and seems to be extremely rare complication following parathyroid irradiation. The four parathyroid glands receive radiation during radiotherapy of neoplasm of the head and neck including lymphoma, Hodgkin's disease, and cancer of the thyroid. Because of their localization, parathyroid glands frequently receive radiation from 131I therapy for thyroid disease. However, parathyroid chief cells have very high radioresistance to necrosis or loss of function. Immediate radiation destruction or ablation of the chief cells to cause acute, symptomatic hypoparathyroidism is exceedingly rare, in fact so rarely documented, that it may not occur [23,24].

Delayed postradiation hypoparathyroidism also seems to be rare. Eipe at al. reported one patient with low serum calcium tetany diagnosed 5 month after 131I therapy with 15.7 mCi [25]. In Glazbrook's review of seven patients, four have received low-dose 131I therapy, two had received external beam conventional radiotherapy, and one received both treatments [26]. The two

who received external beam therapy had metastatic cancer in the neck. The patients who received 131I therapy also received thyroidectomies. Regardless of the fact that probability of unequivocal postradiation delayed parathyroid damage seems to be rare, the actual number of affected patients may be even smaller - due to natural course of underlying disease and short survival time.

## 6. Conclusions

Similarly to the autoimmune disease of parathyroids, in post-laryngectomy or post-radiotherapy damage of the parathyroid glands occurs gradually, initially manifested only as decreased PTH reserve in response to the decreasing serum calcium, eventually leading to hypocalcemia [7,27]. Such chronic hypocalcemia is often well tolerated, and difficult to identify. Despite increasing knowledge about the phenomenon of autoimmune, postoperative or postradiation hypocalcemia, there is still little data concerning long-term follow-up of patients at risk. In literature, cases of post-thyroidectomy hypoparathyroidism diagnosed even as many as 40 years after surgery are described [28]. To our knowledge, described here cases are the first to be presented after such a long time in post-laryngectomy or post-radiotherapy. It may indicate that other such patients are as much likely to develop this rare complication, regardless of the period of time elapsing from the treatment, which implies the need for systematic monitoring of calcemia, as well as the performance of diagnostic tests with the slightest clinical suspicion of hypoparathyroidism.

## Reference

1. Bollerslev J, Rejnmark L, Marcocci C. European Society of Endocrinology Clinical Guideline: Treatment of chronic hypoparathyroidism in adults. *Eur J Endocrinol.* 2015; 173(2): G1-20.
2. Brandi ML, Bilezikian JP, Shoback DS. Management of Hypoparathyroidism: Summary Statement and Guidelines. *J ClinEndocrinolMetab.* 2016; 101(6): 2273-2383.
3. Bilezikian JP, Khan A, Potts JT Jr. Hypoparathyroidism in the Adult: Epidemiology, Diagnosis, Pathophysiology, Target-Organ Involvement, Treatment, and Challenges for Future Research. *J Bone Miner Res.* 2011; 26(10): 2317-2337.
4. Clarke BL, Brown EM, Collins MT. Epidemiology and diagnosis of hypoparathyroidism. *J ClinEndocrinolMetab.* 2016; 101(6): 2284-2299.
5. Betterle C, Garelli S, Presotto F. Diagnosis and classification of autoimmune parathyroid disease. *Autoimmun Rev.* 2014; 13(4-5): 417-422.
6. Lima K, Abrahamsen TG, Wolff AB. Hypoparathyroidism and autoimmunity in the 22q11.2 deletion syndrome. *Eur J Endocrinol.* 2011; 165(2): 345-352.
7. Shoback DM, Bilezikian JP, Costa AG. Presentation of hypoparathyroidism: etiologies and clinical features. *J ClinEndocrinolMetab.* 2016; 101(6): 2300-2312.
8. Bohrer T, Hagemester M, Elert O. A clinical chameleon: postoperative hypoparathyroidism. *Langenbecks Arch Surg.* 2007; 392(4): 423-6.
9. Puziello A, Rosato L, Innaro N. Hypocalcemia following thyroid surgery: incidence and risk factors. A longitudinal multicenter study comprising 2,631 patients. *Endocrine.* 2014.
10. Underbjerg L, Sikjaer T, Mosekilde L, Rejnmark L. Cardiovascular and renal complications to postsurgical hypoparathyroidism: a Danish nationwide controlled historic follow-up study. *J Bone Miner Res.* 2013; 28(11): 2277-2285.
11. Illum F, Dupont E. Prevalences of CT-detected calcification in the basal ganglia in idiopathic hypoparathyroidism and pseudohypoparathyroidism. *Neuroradiology.* 1985; 27: 32-37.
12. Bassar LS, Neale FC, Ireland AW. Epilepsy and electroencephalographic abnormalities in chronic surgical hypoparathyroidism. *Ann Intern Med.* 1969; 71: 507-515.
13. Faig JC, Kalinyak J, Marcus R. Chronic atypical seizure disorder and cataracts due to delayed diagnosis of pseudohypoparathyroidism. *West J Med.* 1992; 157: 64-65.
14. Underbjerg L, Sikjaer T, Mosekilde L, Rejnmark L. Postsurgical hypoparathyroidism--risk of fractures, psychiatric diseases, cancer, cataract, and infections. *J Bone Miner Res.* 2014; 29: 2504-2510.
15. Arlt W, Fremerey C, Callies F. Well-being, mood and calcium homeostasis in patients with hypoparathyroidism receiving standard treatment with calcium and vitamin D. *Eur J Endocrinol* 2002; 146(2): 215-222.
16. Sitges-Serra A, Ruiz S, Girvent M. Outcome of protracted hypoparathyroidism after parathyroidectomy. *Br J Surg.* 2010; 97: 1687-1695.
17. Page C, Strunski V. Parathyroid risk in total thyroidectomy for bilateral, benign, multinodular goitre: report of 351 surgical cases. *J Laryngol Otol.* 2007; 121: 237-241.
18. Thomusch O, Machens A, Sekulla C. The impact of surgical technique on postoperative hypoparathyroidism in bilateral thyroid surgery: a multivariate analysis of 5846 consecutive patients. *Surgery.* 2003; 133: 180-195.
19. Welch KC, McHenry CR. Total thyroidectomy: is morbidity higher for Graves' disease than nontoxic goiter? *J Surg Res Epub ahead of print.* 2011.
20. Basheeth N, O' Cathain E, O' Leary G, Sheahan P. Hypocalcemia af-

ter total laryngectomy: incidence and risk factors. *Laryngoscope*. 2014; 124(5):1128-1133.

21. Lo Galbo AM, Kuik DJ, Lips P. A prospective longitudinal study on endocrine dysfunction following treatment of laryngeal or hypopharyngeal carcinoma. *Oral Oncology*. 2013; 49: 950-955.

22. Thorp MA, Levitt NS, Mortimore S, Isaacs S. Parathyroid and thyroid function five years after treatment of laryngeal and hypopharyngeal carcinoma. *ClinOtolaryngol Allied Sci*. 1999 ;24(2):104-8.

23. Fajardo LF. *Pathology of Radiation Injury*. Masson Publishing, USA, New York. 1982; 206-212.

24. Holden I, Christiansen C. Unchanged parathyroid gland function following irradiation for malignancies of the head and neck. *Cancer*. 1984; 33: 874-877.

25. Eipe J, Johnson SA, Kiamko RT. Hypoparathyroidism following 131I therapy for hyperthyroidism. *Arch. Intern Med*. 1968; 121: 270-271.

26. Glazbrook GA. Effect of decicurie dose of radioactive iodine 131I on parathyroid function. *Am J Surg* 1987; 154:368-373.

27. Cusano NE, Maalouf NM, Wang PY. Normocalcemic Hyperparathyroidism and Hypoparathyroidism in Two Community-Based Non-referral Populations. *J ClinEndocrinolMetab*. 2013; 98(7): 2734-2741.

28. Kelly R, Taggart H. Hypoparathyroidism--presenting 40 years after thyroid surgery. *Ulster Med J*. 1998; 67(1): 63-64.