

The Role of Immunity in Chemotherapy-Resistant Patient with Pembrolizumab: A Case Report

Xiaojuan Shi^{1,2}, Yongjun Guo³, Yi Zhang², Yan Yan¹ and Liping Wang^{1*}

¹Department of Oncology, Hospital of Zhengzhou University, China

²Department of Biotherapy, Hospital of Zhengzhou University, China

³Department of Molecular Pathology, Cancer Hospital of Zhengzhou University, China

Volume 1 Issue 1 - 2018

Received Date: 20 May 2018

Accepted Date: 05 June 2018

Published Date: 12 June 2018

2. Keywords

Pembrolizumab; Immunity; Non-small-cell lung cancer

1. Abstract

1.1. Aims: Approaches are limited for treating advanced Non-Small-Cell Lung Cancer (NSCLC) with multidrug resistance but without ALK and EGFR mutations. Pembrolizumab (KEYTRUDA) brings on unprecedented clinical benefit in various cancer types.

1.2. Results: Here we present a case report of a NSCLC patient had not benefited from Pembrolizumab therapy following chemotherapy. We reviewed the treatment and clinical examination profiles, especially the Immunological indicators. In the ending stage, the patient appeared pneumonia, respiratory failure, septicemia, gastrointestinal hemorrhage, and hypoproteinemia. The percentage of CD4+ and CD8+ T cell in peripheral blood were decreased companion the expression of PD-1. However, the percentage of MDSC (myeloid-derived suppressor cells) was increased continuously. We also detected the expression of PD-1 on T cell in pleural effusion that was under the average value of 24 cases and in the tumor site that was the same with the pleural effusion. Besides the detected CD8+ T lymphocyte infiltration was very low. The overall survival was 6 mouths.

1.3. Conclusion: The detection of Immunological indicators may be an effective strategy for predicting the therapeutic efficacy of PD-1 molecular antibody.

3. Introduction

At late stage NSCLC has greater ability of invasion and develops rapidly [1]. Few therapeutic choices are available for some advanced NSCLC patients, such as those having not ALK and EGFR mutations but multidrug-resistance [1,2]. PD-1 blockade confers NSCLC patients' survival advantage. Although responses are seen in 70% patients after receiving PD-1 antibody, a large part hasn't benefited from such therapy [3]. Herein we present a case of a multidrug-resistant NSCLC patient failed to respond to PD-1 antibody therapy. We describe the clinical examination and the Immunological indicators, indicating the therapeutic efficacy of PD-1 molecular antibody.

4. Method

This study was a case report based on clinical and experimental results. And we also collected 24 cases of malignant pleural effusion to analysis the immune-related indicators.

5. Case Report

A 59-year-old male presented to the First Affiliated Hospital of Zhengzhou University (Zhengzhou, Henan, China) in February 2015 with a 4-month history of continued dull pain of left thorax. No cough, sputum, chest tightness, difficulty breathing, hemoptysis, fever or other symptoms was found. A Computed Tomography (CT) scan of the chest showed a solid mediastina mass with a maximum diameter of 4 cm (**Figure 1a**).

*Corresponding Author (s): Liping Wang, Department of Oncology, Hospital of Zhengzhou University, China, Tel: (86)-371-66964536; Fax: (86)-371-66970906; Email: wlp@zzu.edu.cn

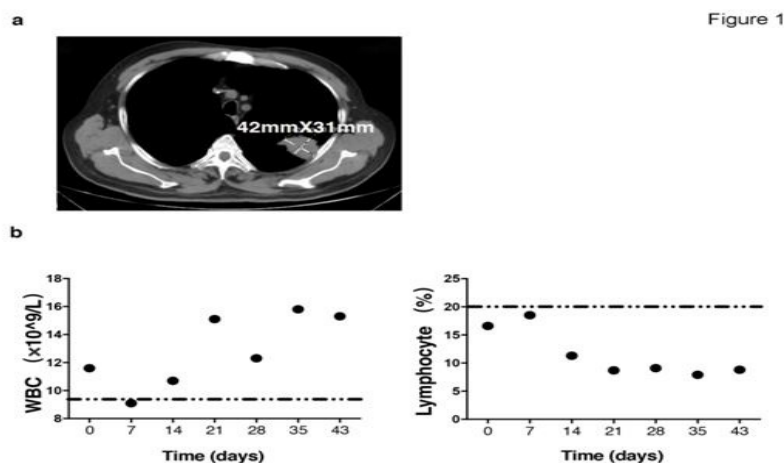


Figure 1: (a) Computed Tomography (CT) scan of the chest showed a solid mediastinal mass with a maximum diameter of 42 mm. (b) White Blood Cells continued to rise higher than the normal level (dotted line), whereas the lymphocytes kept in under the low level (dotted line).

A hypermetabolic appearance was noted on Positron Emission Tomography (PET), and the right side of the ninth ribs showed abnormal metabolic activity. Thus, lung cancer was seriously considered. Confirmed by biopsy, this patient was diagnosed with low-differentiation adenocarcinoma having no ALK and EGFR mutations.

Initially this patient received 4 cycles of combined chemotherapy including Pemetrexed and Cisplatin, and the disease status kept developing. Hence PD-1 antibody (marked as day 0) was adopted at doses of 2mg/kg for every 3 weeks in following course. During PD-1 blockade therapy, this patient characterized with abnormal liver function (AST > 40 U/L) but intact kidney function. Moreover, it was observed that pleural effusion, liver metastases, severe pneumonia (Invasive mechanical ventilation), respiratory failure (PaO₂ = 63.8 mmHg < 80 mmHg and PaCO₂ = 37.3 < 45 mmHg), septicemia (Candida albicans was positive), gastrointestinal

bleeding (fecal occult blood weakly positive), hypoalbuminemia (albumin = 26.9 g/L < 35 g/L). Notably, lymphocytes maintained at very low levels although the total number of peripheral white blood cells kept rising (Figure 1b). Consistently, the proportion of CD4+ T and CD8+ T lymphocytes and PD-1 expression on T cells in peripheral blood was continuously decreased during therapy course. MDSC ratio stably increased, which may contribute to the increase of white blood cells. Furthermore, the percentage of CD4+T and CD8+T in the pleural effusion from this patient was under the average value, when compared with 24 disease state-matched subjects (Figure 2a). Immunofluorescence assay on tumor tissue indicated rare CD8+T infiltration and PD-1 expression (Figure 2b). After 2 cycles of PD-1 monoclonal antibody treatment, this patient died of respiratory failure with survival time of 6 months.

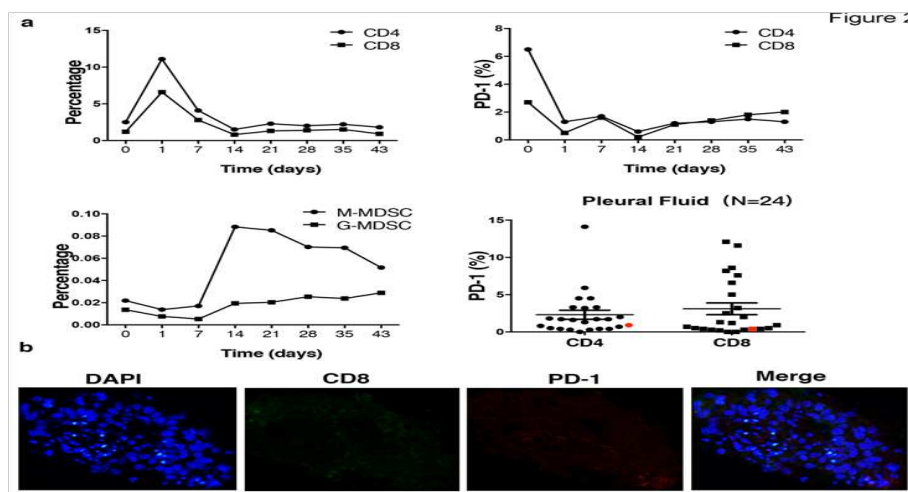


Figure 2: (a) The proportion of CD4 and CD8 lymphocytes and the percentage of PD-1 in peripheral blood were continuously decreased but the ratio of MDSC was increased. The percentages of CD4 and CD8 in the pleural effusion (red point) were under the average value of 24 cases. (b) Immunofluorescence showed low levels of CD8+T infiltration and low PD-1 expression in tumor tissues.

6. Conclusion

In summary, in this case, patient with chemotherapy resistant without ALK or EGFR mutations, to take immune check point antibody therapy, did not benefited from the therapy. We considered the tumor lack of infiltrated lymphocytes, or no therapeutic targets [4]. The proportion of immune-activated cells in peripheral blood remained in low level, and the sustained increasing of the proportion of immunosuppressive cells indicated the ineffectiveness and poor prognosis of the treatment. Therefore, the detection of immunological indicators may be an effective strategy for predicting the therapeutic efficacy of PD-1 molecular antibody.

7. Discussion

Lung cancer is the most common cancer worldwide [5], early stage lung cancer can be treated with curative intent, largely surgery (National Comprehensive Cancer Network. NCCN guidelines: NSCLC (Non- Small Cell Lung Cancer), V4;2014<http://www.nccn.org/professionals/physician_gls/pdf/nscl.pdf> (Accessed 10 June 2014)). However, the majority of patients present with incurable advanced NSCLC stage IIIB or IV, which reflects the aggressive nature of the disease and poor prognosis(National Cancer Institute. Non-small cell lung cancer treatment – for health professionals: general information about non-small cell lung cancer (NSCLC); 2014 <http://www.cancer.gov/cancertopics/pdq/treatment/non-small-cell-lung/health_professional> (Accessed 10 June 2014)). The incidence of epidermal growth factor receptor (EGFR) mutations is approximately 10%, and it is lower in smokers [6]. The EML4-ALK fusion gene is present in approximately 4% of lung cancers and is encountered more occasionally in smokers [7]. Thus, only a small proportion of the total populations of patients with advanced NSCLC are presently candidates for molecular-targeted therapies [8]. At present, one of the main reasons for the treatment of patients with advanced cancer is resistance to chemotherapy [8]. For the patients with multidrug resistance and the absence of gene mutations, the objective response rate of PD-1 monoclonal antibody for the treatment of non-small cell lung cancer patients was 19.4%, and there is still a large part of the patient's condition has not been effectively controlled [3,9].

Here we presented a case of non-small cell lung cancer patient in which two cycles of chemotherapy have been ineffective, followed by two cycles of PD-1 monoclonal antibody therapy, but with rapid progression. We found that the percentage of CD4⁺and CD8⁺T lymphocytes during the PD-1 monoclonal antibody treatment segment continued to decrease, and the expression of PD-1 after a cycle of

treatment maintained at a low level, suggesting that monoclonal antibody treatment is invalid[10]. At the same time, we found that the proportion of two groups of MDSC cells (monocytic MDSC and granulocytic MDSC) continued to rise may be closely related to poor prognosis [11]. In addition, we examined the PD-1 expression of CD4⁺ and CD8⁺T lymphocytes in the pleural effusion, which was much lower than the average in 24 cases of malignant pleural effusion, suggesting that PD-1 monoclonal antibody therapy could not be performed in this patient's immune microenvironment in an effective role [12]. In addition to our immunofluorescence detection of tumor tissue, we found that tumor infiltration of CD8 T lymphocytes rarely, and the PD-1 expression is lower, suggesting that patients with shorter survival time [13-15].

8. Conflict of Interest

Authors do not declare any financial support or relationships that may pose a conflict of interest.

References

1. Novello S, Barlesi F, Califano R, Cufer T, Ekman S, Levra MG, et al. Metastatic non-small-cell lung cancer: ESMO Clinical Practice Guidelines for diagnosis, treatment and follow-up. *Ann Oncol.* 2016;27(suppl 5):v1-v27.
2. Peters S, Kerr KM, Stahel R. PD-1 blockade in advanced NSCLC: A focus on pembrolizumab. *Cancer Treat Rev.* 2018;62:39-49.
3. Garon EB, Rizvi NA, Hui R, Leighl N, Balmanoukian AS, Eder JP, et al. Pembrolizumab for the treatment of non-small-cell lung cancer. *N Engl J Med.* 2015;372(21):2018-28.
4. Hui R, Garon EB, Goldman JW, Leighl NB, Hellmann MD, Patnaik A, et al. Pembrolizumab as first-line therapy for patients with PD-L1-positive advanced non-small cell lung cancer: a phase 1 trial. *Ann Oncol.* 2017;28(4):874-81.
5. Jemal A, Bray F, Center MM, Ferlay J, Ward E, Forman D. Global cancer statistics. *CA: a cancer journal for clinicians.* 2011;61:69-90.
6. Reck M, Popat S, Reinmuth N, De Ruyscher D, Kerr KM, Peters S, et al. *Ann Oncol.* 2014;25 Suppl 3:iii27-39.
7. Shi JY, Yang LX, Wang ZC, Wang LY, Zhou J, Wang XY, et al. CC chemokine receptor-like 1 functions as a tumour suppressor by impairing CCR7-related chemotaxis in hepatocellular carcinoma. *J Pathol.* 2015;235(4):546-58.
8. Hirsch FR, Suda K, Wiens J, Bunn PA, Jr. New and emerging targeted treatments in advanced non-small-cell lung cancer. *Lancet.* 2016;388(10048):1012-24.
9. Mountzios G, Linardou H, Kosmidis P. Immunotherapy in non-small cell lung cancer: the clinical impact of immune response and targeting. *Ann*

Transl Med. 2016;4(14):268.

10. Zhang T, Xie J, Arai S, Wang L, Shi X, Shi N, et al. The efficacy and safety of anti-PD-1/PD-L1 antibodies for treatment of advanced or refractory cancers: a meta-analysis. *Oncotarget*. 2016;7(45):73068-73079.

11. Pyzer AR, Cole L, Rosenblatt J, Avigan DE. Myeloid-derived suppressor cells as effectors of immune suppression in cancer. *Int J Cancer*. 2016;139(9):1915-26.

12. Marvel D, Gabrilovich DI. Myeloid-derived suppressor cells in the tumor microenvironment: expect the unexpected. *J Clin Invest*. 2015;125(9):3356-64.

13. Ottensmeier CH, Perry KL, Harden EL, Stasakova J, Jenei V, Fleming J, et al. Upregulated Glucose Metabolism Correlates Inversely with CD8+ T-cell Infiltration and Survival in Squamous Cell Carcinoma. *Cancer Res*. 2016 Jul 15;76(14):4136-48.

14. Oguejiofor K, Hall J, Slater C, Betts G, Hall G, Slevin N, et al. Stromal infiltration of CD8 T cells is associated with improved clinical outcome in HPV-positive oropharyngeal squamous carcinoma. *Br J Cancer*. 2015 Sep 15;113(6):886-93.

15. Sivan A, Corrales L, Hubert N, Williams JB, Aquino-Michaels K, Earley ZM, et al. Commensal *Bifidobacterium* promotes antitumor immunity and facilitates anti-PD-L1 efficacy. *Science*. 2015;350(6264):1084-9.